

Recently described subtypes of renal tumours (adults)

Dr Jonathan H Shanks

*The Christie NHS
Foundation Trust,
Manchester, UK*



Malignant renal tumours - adults

- Renal cell carcinoma
 - Conventional (clear cell) renal carcinoma
 - Papillary renal cell carcinoma
 - Chromophobe renal cell carcinoma
 - Collecting duct carcinoma
 - Renal cell carcinoma, unclassified [exclude metastasis!]
- Rare tumours e.g. adult Wilms' tumour
- Transitional cell carcinoma of the renal pelvis
- Metastases (lung, melanoma, GI tract)



The Heidelberg/Rochester classification of renal cell tumours (1997)

Benign

- Renal oncocytoma
- Papillary renal adenoma
- Metanephric adenoma
- Metanephric adenofibroma

Malignant

- Conventional RCC
- Papillary RCC
- Chromophobe RCC
- Collecting duct carcinoma
- RCC unclassified
- [metastases]

[Wilms' tumours not included in the classification]



Subsequent additions to classification of renal cell carcinoma

- Papillary renal carcinoma subtyping:
 - type 1 (~70% cases: small nuclei, inconspicuous nucleoli grade 1 or 2, +/-nuclear grooves, rather scanty basophilic cytoplasm)
 - type 2 (~30% cases: nuclei large with prominent nucleoli - grade 3, pseudostratification common)
- Hereditary papillary renal cell carcinoma
- Solid variant papillary renal cell carcinoma
- MiTF/TFE family translocation-associated renal cell carcinoma (e.g.carcinoma associated with Xp11.2 translocations/*TFE3* gene fusion)
- Clear cell (tubulo)papillary renal cell carcinoma
 - Renal angiomyoadenomatous tumour (RAT)
- Acquired cystic disease-associated renal cell carcinoma
- Hereditary leiomyomatosis associated renal cell carcinoma
- [Renal cell carcinoma associated with succinate dehydrogenase mutations]*
- [*ALK* translocation associated RCC]*
- Medullary carcinoma (patients with sickle cell trait)
- Tubulocystic carcinoma (previously known as 'low grade collecting duct carcinoma')
- Mucinous tubular and spindle cell carcinoma
- [Thyroid-like follicular carcinoma of kidney]*
- Hybrid oncocytic tumour (HOCT)
- Renal cell carcinoma following therapies (post-neuroblastoma, post-transplant, post-chemotherapy)



*provisional entity

The International Society of Urological Pathology (ISUP) Vancouver Classification of Renal Neoplasia

Srigley JR, Delahunt B, Eble JN, Egevad L, Epstein JI, Grignon D, Hes O, Moch H, Montironi R, Tickoo SK, Zhou M, Argani P; The ISUP Renal Tumor Panel. Am J Surg Pathol. 2013;37:1469-1489.



Hereditary papillary renal carcinoma

- Autosomal dominant with low penetrance (approx 50% family members affected)
- Hundreds to 1000s tumours in each kidney
- Type 1 papillary renal cell carcinoma with activating mutations of c-met at 7q31 (same mutation found in 13% of sporadic type 1 papillary RCCs)



Metanephric adenoma

- Solid variant papillary renal carcinoma (or epithelial predominant nephroblastoma in children) are differential diagnoses
- Immunohistochemistry useful to distinguish from papillary renal carcinoma
- Absence of blastema, mitotic figures and a fibrous capsule helps distinguish MA from nephroblastoma (Wilm's)
- Absence of a fibrous capsule at the periphery also helps distinguish MA from papillary renal carcinoma
- There are rare reports of nephroblastoma or papillary renal cell carcinoma arising in MA/metanephric adenofibroma



Metanephric adenoma and solid variant of papillary renal cell carcinoma: common and distinctive features

Padilha MM *et al.* *Histopathology* 2013;62:941-953.

Metanephric adenoma

- Unencapsulated
- Scanty cytoplasm throughout
- No high grade nuclei
- Polypoid branching fronds with stroma
- No multifocality
- WT1+ve (90% cases)
- EMA and AMACR_[in all but one]
- -ve
- Most disomic for ch 7 and 17

Solid variant papillary RCC

- Often encapsulated
- Scattered cells with abundant cytoplasm
- May have high grade nuc.
- No polypoid branching fronds
- May be multifocal
- WT1-ve
- EMA and AMACR +ve
- Most show trisomy 7 and 17



Metanephric adenoma and solid variant of papillary renal cell carcinoma: common and distinctive features

Mantoan Padilha MM *et al.* *Histopathology* 2013;62:941-953.

Features common to both:

- Nuclear grooves
- Tightly pack ill-defined tubules or solid sheets
- Psammoma bodies +/- dystrophic calcification
- Glomeruloid bodies
- CK7 +ve in 57% MAs (focal in 58%, diffuse in 17%); diffusely and strongly +ve in all solid papillary carcinoma
- CD57 +ve in both in high %
- Foamy histiocytes (though more frequent in solid pap RCC)



Clues to diagnosis of translocation associated renal cell carcinoma

- Varied architectural patterns with prominent papillary component with clear cell component
- Generally, but not restricted to, younger patients
- Calcification, especially psammomatous calcification
- May have voluminous cytoplasm
- More often absent or low expression of cytokeratins (not always!)
- TFE3 positive for Xp11.2 translocation carcinoma



Renal cell carcinoma associated with Xp11.2 translocation

- Mainly tumours of children and young adults
- In children often present at higher stage but preliminary studies suggest they may not be more aggressive than other types; more aggressive behaviour in adults
- Have overlapping histological features with other RCCs
- All have translocations involving *TFE3* gene at Xp11.2 (translocation also found in alveolar soft part sarcoma)
- Nested, solid, alveolar or tubulopapillary architecture; cells with voluminous clear to acidophilic cytoplasm. Frequent psammomatous calcification
- Immunohistochemistry differs from other RCCs: no or only focal EMA, AE1/3, CAM5.2 and vimentin. CAIX typically negative. Racemase (AMACR) often diffusely +ve



TFE3 immunohistochemistry

- TFE-3, TFE-B, TFE-C and MiTF comprise the microphthalmia (TFE-3/MiTF) transcription factor subfamily and transcription factors and have homologous DNA binding domains with functional overlap
- An antibody against the C-terminus of TFE3 available; antibody against TFEB also available
- TFE3 is a marker for alveolar soft part sarcoma and renal carcinomas with Xp11 translocation (strong nuclear expression). Strong expression also seen in granular cell tumours
- Some cases of paediatric renal cell carcinoma with TFE3 gene fusions lack TFE3 expression immunohistochemically
- Low level of expression of TFE3 seen in many normal tissues
- Cytoplasmic staining should be ignored



Renal cell carcinoma associated with Xp11.2 translocation

Variant translocations:

- $t(X;1)(p11.2;q21)$ ~78% cases [*PRCC-TEF3*]
- $t(X;1)(p11.2;p34)$ ~20% cases [*PSF-TEF3*]
- $t(X;17)(p11.2;q25)$ rare [*ASPL-TEF3*]*
- $inv(X)(p11;q12)$ [nonO-TFE3]
- $t(X;17)(p11.2;q23)$ [CLTC-TFE3]

[alveolar soft part sarcoma = $der(17)t(X;17)(p11.2;q25)$ *]

- Insufficient information on long-term follow up but lymph node mets common
- 10-15% cases have a history of previous cytotoxic chemotherapy (paediatric cases)



Xp11 cases in adults

- 28 cases reported in adults (>20 yrs old) in series by Argani et al (2007)
- F:M= 22:6
- Most presented at advanced stage (14 were stage IV)
- Perirenal LN mets in 11/13 cases with node sampling
- Psammomatous calcification in 14 cases (numerous and widespread in 7)
- Most were either negative or weakly positive for cytokeratins, EMA and vimentin



The evolving story of renal translocation carcinomas

Argani P and Ladanyi M *Am J Clin Pathol* 2006;126:332-334

Xp11 translocation renal cell carcinoma in adults: expanded clinical, pathologic and genetic spectrum

Argani P *et al Am J Surg Pathol* 2007;31:1149-1160



A distinctive pediatric renal neoplasm characterised by epithelioid morphology, basement membrane production, focal HMB45 immunoreactivity and t(6;11)(q21.1;q12) chromosome translocation Argani P *et al* Am J Clin Pathol 2001;158:2089-2096

- Nested architecture
- Biphasic pattern with clusters of small cells clustered around basement membrane material amongst sheets of large cells with eosinophilic cytoplasm
- Some closely resemble Xp11 translocation carcinomas
- Calcification rare to absent
- Usually negative for cytokeratins. Positive for melanocytic markers HMB45 and Melan A
- Involves gene fusion at 6p21 involving TFEB
- TFEB protein, demonstrable by immuno is sensitive and specific for these neoplasms
- TFEB is a member of the same MITF/TFE subfamily of transcription factors as TFE3
- Very recently, MITF positivity found in some Xp11 translocation carcinomas (positivity depends on fusion partner – more often with PSF-TFE3 or CLTC-TFE3)
- Reported cases organ-confined with good prognosis though reported follow-up limited



Melanotic Xp11 translocation renal cancers: A distinctive neoplasm with overlapping features of PEComa, carcinoma and melanoma.

Argani P *et al* Am J Surg Pathol 2009;33;609-619

- 2 cases described in children with TFE-3 translocations, expressing TFE-3 by immuno
- Melan A and HMB45 +ve but S100 and MiTf -ve
- Cytokeratins, EMA, CD10, RCC Ma -ve



Renal translocation carcinomas. Clinicopathologic, immunohistochemical and gene expression profiling analysis of 31 cases with a review of the literature

Camparo P *et al.* Am J Surg Pathol 2008;35:656-670

- 29 cases were TFE3 translocation carcinomas
- 2 cases were TFEB translocation carcinomas
- Mixed papillary/nested patterns most frequent with common microcalcifications, regardless of type of translocation
- CD10 and AMACR expressed in all cases
- Melanocytic markers expressed weakly in all but two



Clear cell (tubulo) papillary renal cell carcinoma

- A recently recognised entity that has clear cells and papillary and/or tubulopapillary architecture but differs morphologically, immunohistochemically and cytogenetically from both conventional (clear cell) and papillary renal carcinoma
- Initially described in end-stage kidneys with acquired cystic disease but increasingly recognised outside this setting
- Often has cystic and/or tubulocystic areas as well as papillary areas
- Tumour nuclei mostly have a linear arrangement away from the basal aspect of the cell (like nuclei in secretory endometrium)
- Foamy macrophages and/or necrosis not seen
- Low nuclear grade (up to Fuhrman 2)
- Diffusely +ve for CK7 and CAIX (latter shows cup-like staining) and 34BE12
- Negative for racemase (AMACR) and (most cases) –ve or focally +ve for CD10
- No evidence of 3p losses, VHL mutation or polysomy 7 or 17
- Differential diagnoses = conventional (clear cell), papillary and translocation carcinomas
- Limited experience suggests an indolent behaviour.



Clear cell (tubulo) papillary renal cell carcinoma

- Shows some overlap with renal angiomyoadenomatous tumour (RAT)
- ?May be ends of a spectrum within 1 entity
- Absence of 3p/VHL abnormalities
- Absence of chromosome 7 and 17 abnormalities
- May contain variable amounts of smooth muscle stroma (characteristic of RAT)
- These are low grade tumours with indolent behaviour, unlike conventional (clear cell) RCC



Renal cell carcinoma with areas mimicking renal angiomyoadenomatous tumour/clear cell papillary renal cell carcinoma

Peterson F *et al. Hum Pathol* 2013;44:1412-1420

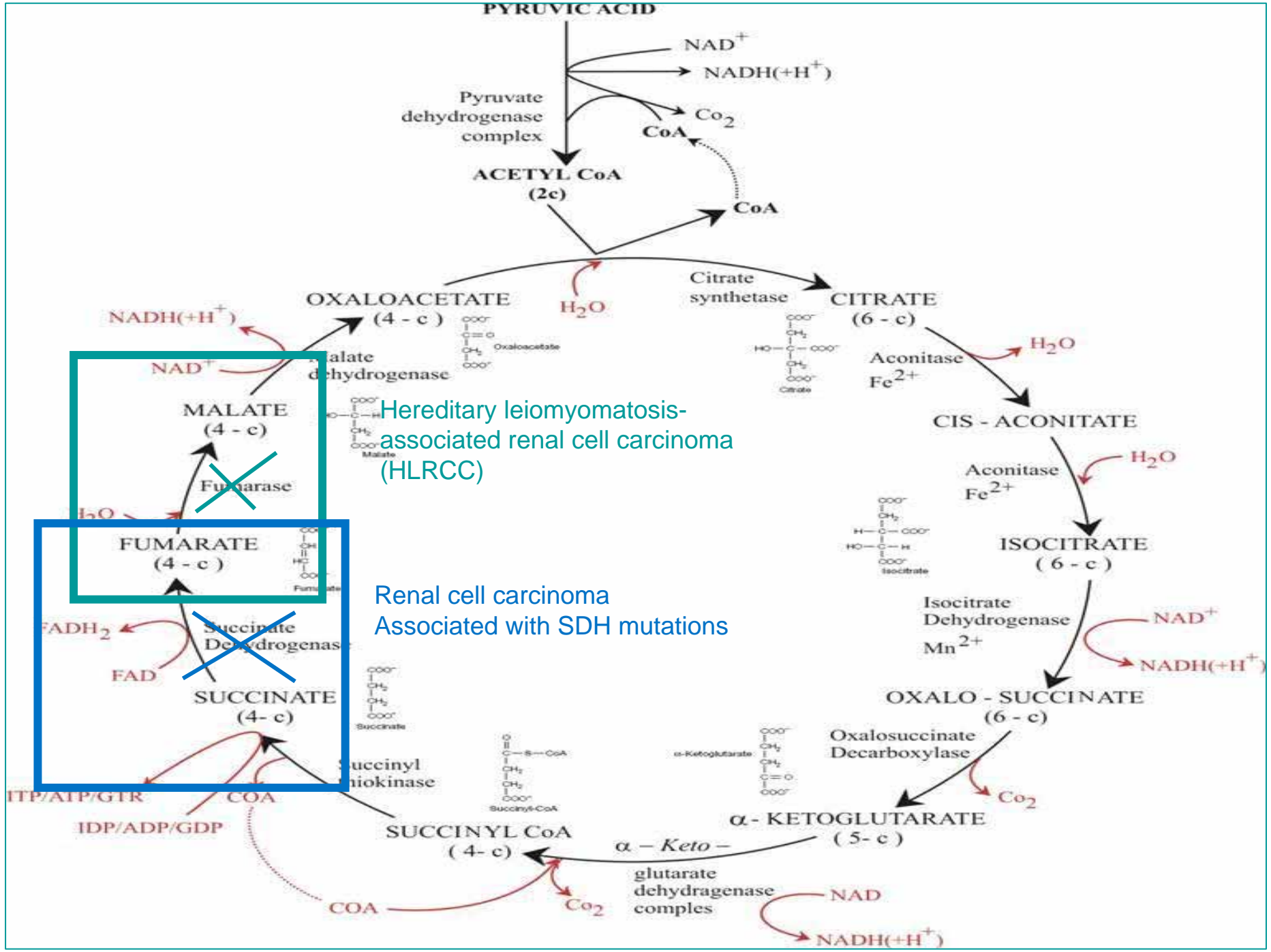
- 8 cases described, most of which were conventional (clear cell) RCCs having focal areas of RAT/clear cell papillary morphology, including CK7 expression
- RAT/clear cell papillary morphology can be seen focally in otherwise conventional (clear cell) RCC



Recently recognised associations of renal tumours with mutations of mitochondrial complex genes (involved in Krebs cycle)

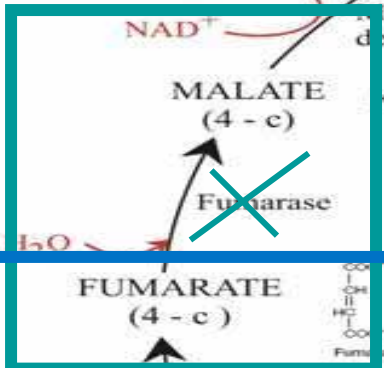
- Hereditary leiomyomatosis and renal cell carcinoma (involves germline heterozygosity and somatic loss of fumarate hydratase gene)
- Succinate dehydrogenase mutations (B, C and D) – also associated with familial pheochromocytoma and GISTs (SDHB and D mutations associated with renal tumours)
— see Gill AJ *et al. Am J Surg Pathol* 2011;35:1578-85.





Hereditary leiomyomatosis-associated renal cell carcinoma (HLRCC)

Renal cell carcinoma Associated with SDH mutations



Hereditary leiomyomatosis-associated renal cell carcinoma (HLRCC)

- Autosomal dominant
- Associated with cutaneous and uterine leiomyomas
- Fumarate hydratase mutation present
- Histologically and clinically aggressive tumours with overlapping features of type 2 papillary renal cell carcinoma and/or collecting duct carcinoma
- Often multinodular with stromal desmoplasia
- Large orangeophilic nucleolus resembling CMV inclusion



Renal tumours associated with germline SDHB mutations show distinctive morphology

Gill AJ et al. Am J Surg Pathol 2011;35:1578-85

- A provisional entity in the new classification
- Often young age at presentation (<30 years frequent)
- Cuboidal cells with bubbly eosinophilic cytoplasm
- Distinctive cytoplasmic inclusions (vacuolated or containing eosinophilic fluid-like material)
- Negative for SDHB by immunohistochemistry
- Generally indolent clinical behaviour, unless sarcomatoid differentiation



Renal tumours associated with end-stage renal disease

- Acquired cystic disease-associated RCC
- Clear cell (tubulo)papillary renal cell carcinoma
- Conventional (clear cell) renal carcinoma
- Papillary renal carcinoma
- Chromophobe renal carcinoma
- Collecting duct carcinoma
- Oncocytoma

x100 fold increase in incidence of renal tumours for end stage renal patients on dialysis (3-7% patients with end stage kidneys)



Acquired cystic disease-associated renal cell carcinoma

- Most common type of renal carcinoma in end-stage kidneys, specifically those with acquired cystic disease
- Usually (but not always) in patients on dialysis (incidence increases with time on dialysis)
- Tumour cells have eosinophilic cytoplasm, cribriform/sieve-like appearance (intra and inter cytoplasmic vacuoles)
- Oxalate crystals present
- Racemase (AMACR +ve); CK7 typically negative
- Most diagnosed at low stage (and non-aggressive unless sarcomatoid change present)



Medullary renal cell carcinoma

- High grade tumour with similar morphology to collecting duct renal carcinoma
- Age range 5-40 years
- Need to exclude high grade urothelial carcinoma and metastatic carcinoma to kidney
- Almost all cases in patients with sickle cell trait (rarely associated with sickle cell anaemia)
- Loss of INI-1 (BAF 47) by immunohistochemistry [NB loss of INI-1 is not specific to medullary carcinoma as 15% collecting duct carcinoma also show INI-1 loss, but its presence is against medullary carcinoma].
- 34BE12 typically – ve
- Very aggressive behaviour



Tubulocystic renal cell carcinoma

- <70 cases reported in the literature. M:F = 7:1
- Low stage at presentation <10% progress, despite 'high grade' nuclei
- In older texts e.g. 3rd AFIP fascicle called 'low grade collecting duct carcinoma'
- Well circumscribed 'bubble-wrap appearance'
- Tubules/cysts lined by a single layer of hobnail cells or cubo-columnar cells. Mitotic figures/necrosis rare/absent.
- Large nuclei, often prominent nucleoli, eosinophilic cytoplasm
- Pure tubulocystic growth pattern
- Fuhrman grading not recommended because prominent nucleoli frequent yet usually good outcome



Tubulocystic carcinoma of the kidney with poorly differentiated foci: a series of 3 cases with fluorescence in situ hybridization analysis.

Al-Hussain TO *et al. Hum Pathol.* 2013;44:1406-11

Three rare cases reported of tubulocystic renal carcinoma with admixed areas with features of another high grade component e.g. collecting duct carcinoma or papillary carcinoma



Mucinous tubular and spindle cell carcinoma

Paner et al 2006; Cossu-Rocca, 2006

- A biphasic tumour with tubules and low grade spindle cells (with stromal mucin)
- Important not to confuse spindle cell presence with sarcomatoid differentiation
- AMACR, CK7 +ve in both in most cases
- CD10 usually negative or focal (unlike papillary RCC)
- Trisomy 7 and 17 and loss of Y not seen in mucinous tubular and spindle cell carcinoma (unlike in papillary renal carcinoma).
- Multiple chromosome losses found. FISH can be used in differential diagnosis with papillary RCC
- Favourable clinical outcome (46 cases, mets in 2, no tumour related deaths but recently described entity)



Mucinous tubular and spindle cell carcinoma – variant features

- Spindle cell predominant (could be mistaken for a sarcoma)
- Tubular predominant
- Scant/absent mucin
- Focal clear cells
- Vacuolation resembling signet ring cells
- True sarcomatoid differentiation (very rare)



Mucinous tubular and spindle cell carcinoma – differential diagnosis

- Papillary carcinoma with sarcomatoid areas or other sarcomatoid carcinoma
- Sarcoma for spindle cell predominant variant
- Papillary renal cell carcinoma with low grade spindle cell foci
 - Mucin absent
 - Trisomy 7 and 17 present
 - CD10 more often +ve



Thyroid-like follicular carcinoma of kidney

- A provisional entity in the new classification
- First described in 2004
- <10 accepted cases in the literature (extremely rare)
- Slight female predominance (1:2)
- Well circumscribed with a fibrous capsule
- Striking follicular architecture with macro- and micro- follicles + inspissated colloid-like material. No clear cells.
- Nuclei have uniform chromatin and inconspicuous nucleoli
- Usually indolent but 2 patients developed regional LN metastases
- Lack papillae and nuclear changes of papillary thyroid carcinoma
- Differential diagnosis = metastatic carcinoma from thyroid
- Thyroglobulin and TTF-1 negative in thyroid-like follicular carcinoma of kidney, unlike metastases from thyroid



Metastatic papillary carcinoma to the kidney: report of two cases mimicking primary renal carcinoma and review of the literature

Falzarano SM, Chute J and Magi-Galuzzi C. *Pathology* 2013;45:89-93

- Look for nuclear features of papillary carcinoma (absent in primary renal tumours; present in metastatic papillary carcinoma from thyroid)
- Immunohistochemistry is useful (primary renal thyroid-like tumours are negative for TTF-1 and thyroglobulin, unlike metastases from thyroid)
- PAX8 wouldn't help (positive in both)



Post-therapy renal cell carcinomas

- Classically described following treatment for neuroblastoma
- May follow chemotherapy for other tumours e.g. Wilms tumour
- x20 incidence compared with general population
- Often unclassified morphology and high grade. May have an oncocytoid appearance but varied morphology/architecture
- TFE3 or TFEB translocation carcinomas follow previous therapy for a wide range of other tumours e.g. leukaemia, melanoma, sarcoma, thyroid, breast carcinoma



Mesenchymal tumours of kidney

- Angiomyolipoma
 - Epithelioid variant/PEComa
- Solitary fibrous tumour
- Synovial sarcoma
- Other sarcomas



Angiomyolipoma

- F:M = 5:1
- Alterations in tuberous sclerosis genes TSC1 (hamartin at 9q34) or TSC2 (tuberin at 16p13.3). TSC2 involved in most sporadic AMLs
- Multiple +/- bilateral angiomyolipomas or presentation before puberty is at least strong presumptive evidence of tuberous sclerosis
- Renal vein involvement may be found without aggressive behaviour; regional lymph nodes may have multifocal involvement rather than being considered metastatic disease



Angiomyolipoma - immunohistochemistry

- +ve for HMB45 (often focal), melan A, MiTF, tyrosinase, h-caldesmon, alpha SMA, desmin
- -ve for S100 (except in fat), cytokeratins (except for AMLEC cases where cysts +ve)



Angiomyolipoma (AML) variants

- Epithelioid AML
- Smooth muscle predominant AML (spindle cell)
 - could mimic leiomyoma, leiomyosarcoma or sarcomatoid RCC. Often capsular ‘capsulomas’
- Predominantly lipomatous AML
- AML with epithelial cysts (AMLEC) – rare variant with cysts derived from renal tubules lined by cuboidal or hobnail cells. CD10, ER, PR +ve Mullerian stroma around the cysts



Epithelioid AML

- >50% epithelioid cells required for diagnosis by most experts
- Higher incidence of epithelioid AML in tuberous sclerosis syndrome
- Regarded as potentially malignant, unlike other AML subtypes. % of malignant cases differs according to the series and some may have referral consultation bias resulting in overestimate of proportion of clinically malignant cases
- Can be mistaken for renal cell carcinoma or even metastatic melanoma
- Presence of pleomorphic tumour giant cells in a renal tumour should always raise the possibility of epithelioid AML



Epithelioid AML: predictors of malignancy

- Pure epithelioid morphology
- Large size (>7cm)
- Perirenal tumour extension
- Mitotic figures >2/10HPF
- Necrosis
- Cellular anaplasia

Greater predictive value when combined

TSC1 gene often abnormal.

May be a response to mTOR inhibitors for malignant cases



Rare tumours with epithelial and mesenchymal differentiation

- Cystic nephroma - entirely cysts + septa with no solid expansile areas
 - septa should be <5mm thick
 - epithelial elements may be flat, hobnailed, cuboidal, columnar, urothelial-like or focally clear cell
- Mixed epithelial and stromal tumour (MEST)
 - variable amounts of solid components – predominantly solid rather than cystic

Several publications favour both the above being the same entity with two end of a spectrum. F:M = 8:1 (suggest hormonal role; often history of HRT; ER and PR +ve in stroma)

MEST was previously known as ‘cystic hamartoma of the renal pelvis’



Cystic nephroma

- Multicystic mass surrounded by fibrous pseudocapsule
- Cysts and septa with no solid nodules. Cyst lining is flattened, hobnail or cuboidal
- Septa may contain occasional mature tubules
- No epithelial cells with clear cytoplasm in septa
- Stroma often ovarian-like; skeletal muscle absent
- Benign
- Differential diagnosis = multilocular cystic RCC (lined by clear cells without ovarian-type stroma; clear cells in septa without expansile growth; ER and PR –ve in stroma)



Cystic nephroma and mixed epithelial and stromal tumor of kidney: a detailed clinicopathologic analysis of 34 cases and proposal for renal epithelial and stromal tumor (REST) as a unifying term

Turbiner J et al Am J Surg Pathol 2007;31:489-500

Very rare tumours at the MEST end of the spectrum have developed a malignant epithelial component or a malignant stromal component (e.g. rhabdomyosarcoma, synovial sarcoma, chondrosarcoma). All typical cases are benign.



Juxtaglomerular cell tumour (reninoma)

- Closely resembles glomus tumour, occasionally has a spindle cell element
- Clinically marked systemic hypertension
- Unlike glomus tumour is CD34+ve, c-kit +ve, renin +ve
- 'Endocrine atypia' may occur
- Onion-skinning of blood vessels may occur within the tumour, possibly as a result of marked hypertension



Neuroendocrine/neural tumours

- Carcinoid
- Small cell carcinoma
- Large cell neuroendocrine carcinoma
- PNET/Ewings
- Paraganglioma
- Others



Renal carcinoid tumour

- 20% arise in a horseshoe kidney (60 to 85 times more frequent in a horseshoe kidney than a normal kidney)
- Exclude metastatic carcinoid tumour to kidney (often multiple with lymphovascular invasion)

[McVey RJ, Banerjee SS, Eyden BP, Reeve RS, Harris M. Carcinoid tumour originating in a horseshoe kidney. In Vivo 2002;16:197-9]

