MANCHESTER 1824

The University of Manchester

Central Manchester University Hospitals NHS
NHS Foundation Trust

# Handling of Lower GI Specimens


Prof Ray McMahon

Histopathology Department

Manchester Royal Infirmary


Bryan Warren School

Sarajevo

November 2016

MANCHESTER 1824

The University of Manchester

# Approach to Cut Up – Large Intestine

Professor Ray McMahon

Manchester Royal Infirmary

University of Manchester

Wednesday 9 March 2016

RCOG, London

British Division of the International Academy of Pathology

www.bdiap.org

# Approach to Cut Up – Large Intestine

Prof Geraint Williams
Wales College of Medicine
Cardiff University

CARDIFF UNIVERSITY
PRIFYSGOL CAERDYDD

coleg meddygaeth cymru
wales college of medicine

# 8th BDIAP Seminar for Trainees in Histopathology
# Approach to Cut-Up: Macroscopic examination as the precursor to accurate microscopic interpretation

## Lower GI tract

**Professor Neil A Shepherd**

**Gloucester & Cheltenham**

**Kings Fund, London**

**3 March 2015**

# The accurate macroscopic assessment of intestinal pathology: it's all about attitude……

# What we will consider in the ‘lower GI’ tract

Resection specimens
Polyps and local resections

Inflammatory conditions

Other benign pathologies

# Before you start

- Know your anatomy
  - the peritoneum and its reflections
  - the mesentery and omentum
  - the blood vessels
  - adjacent structures
    - bladder, prostate, seminal vesicles, uterus, ovaries

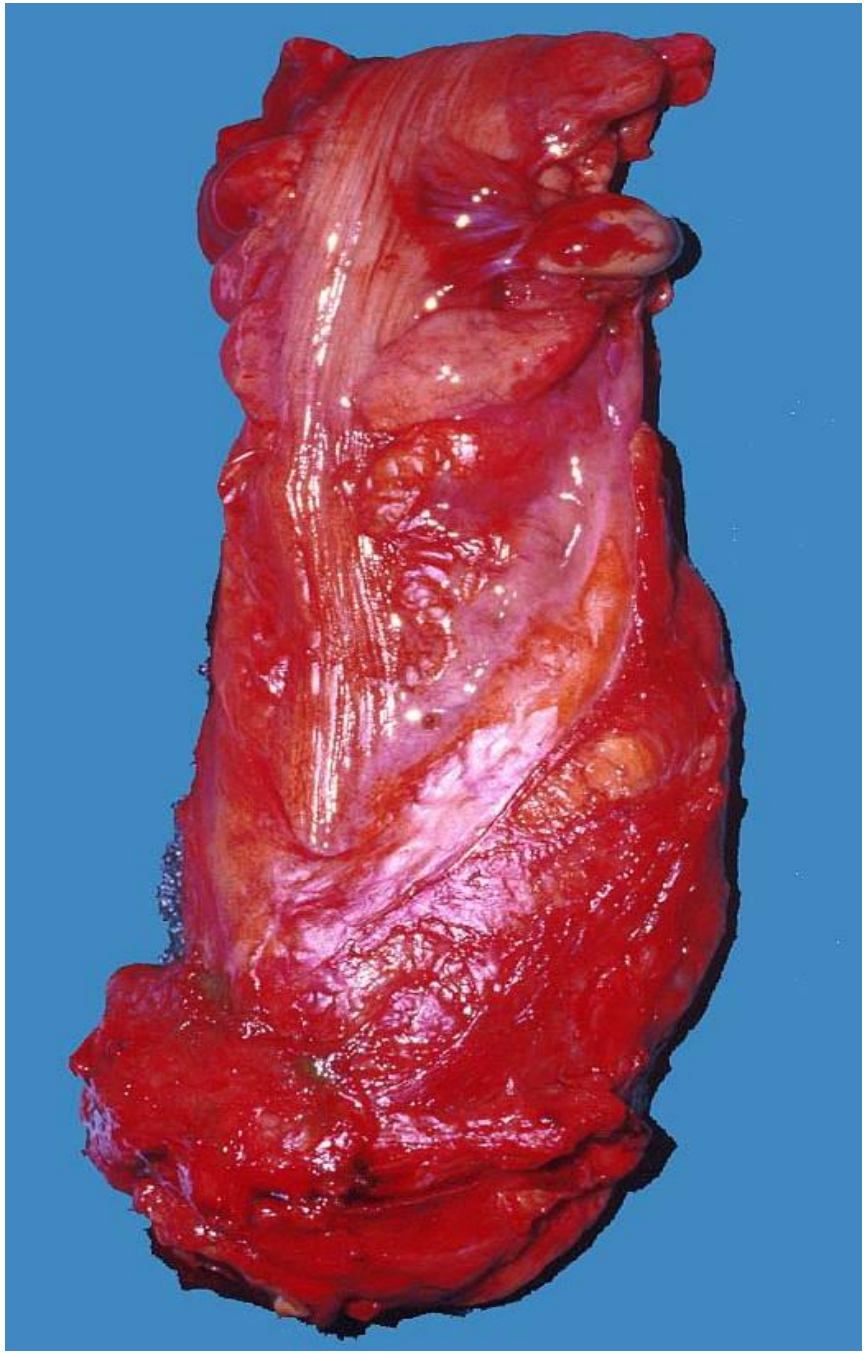

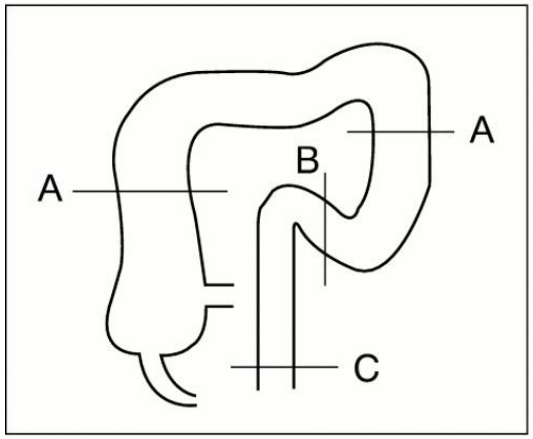
A
B
A
C

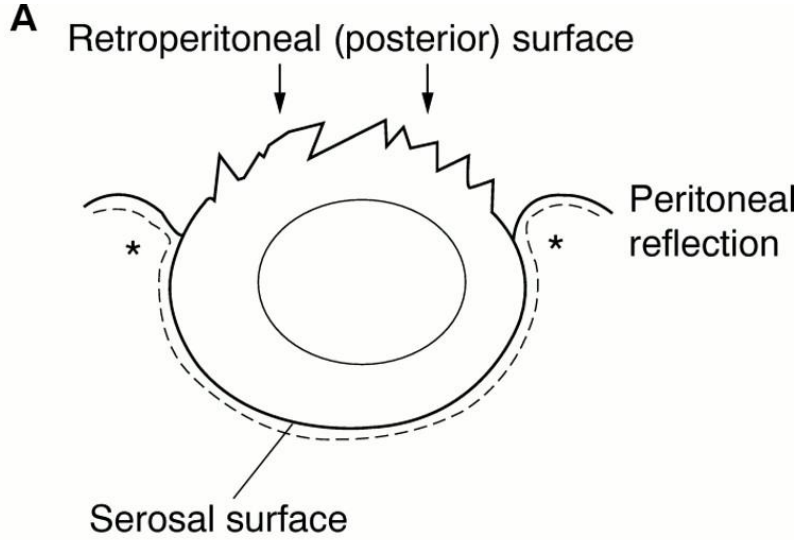
A
Retroperitoneal (posterior) surface
Peritoneal reflection
*
*
Serosal surface

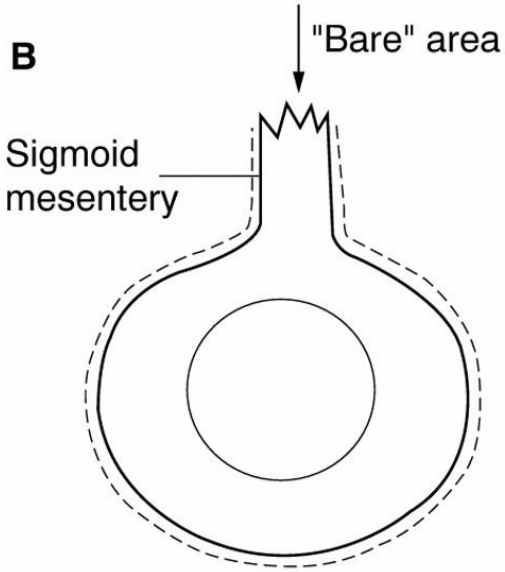
B
"Bare" area
Sigmoid mesentery

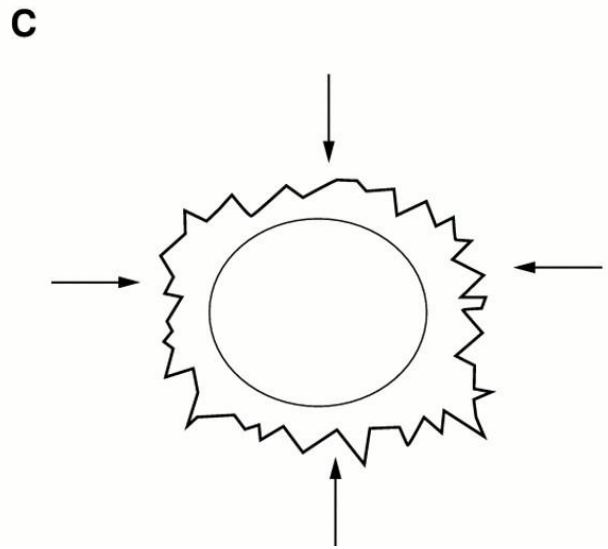
C

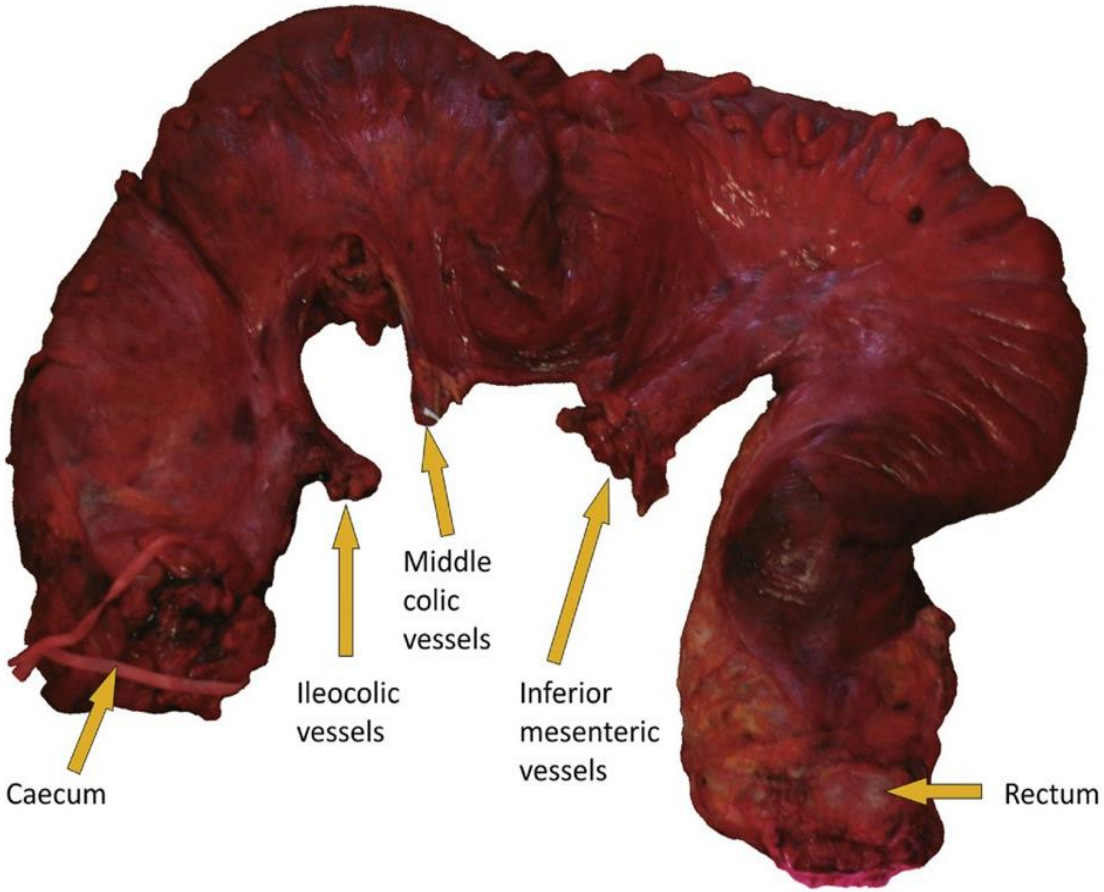


**Figure 32.2** Fresh subtotal colectomy specimen for multiple colonic tumours: the mesentery has been removed intact and all three major vascular ties are seen.

*Morson and Dawson's Gastrointestinal Pathology*, Fifth Edition. Edited by Neil A. Shepherd, Bryan F. Warren, Geraint T. Williams, Joel K. Greenson, Gregory Y. Lauwers and Marco R. Novelli.

# Before you start

- know your anatomy
- learn surgeon-speak
  - operations
    - Hartmann's procedure
    - anterior resection, abdominoperineal excision
    - right and left hemicolectomy
  - acronyms
    - EMR, TEMS, TART, TME
  - others
    - pouches, columnar cuffs
    - ostomies
    - curative vs palliative

# Before you start

- know your anatomy
- learn surgeon-speak
- get to know the endoscopists, surgeons and their support staff

# Before you start

- know your anatomy
- learn surgeon-speak
- get to know the endoscopists, surgeons, and their support staff
- receive the specimen fresh (if possible)

# Before you start

- know your anatomy
- learn surgeon-speak
- get to know the endoscopists, surgeons, and their support staff
- receive the specimen fresh (if possible)
- find out as much as you can about the case
  - request form
  - MDT records - diagnosis, stage, family history
  - pathology laboratory computer
  - previous treatment that might affect the pathology

# Before you start

- know your anatomy
- learn surgeon-speak
- get to know the endoscopists, surgeons, and their support staff
- receive the specimen fresh (if possible)
- find out as much as you can about the case
- don’t be coy about asking the surgeon to show you what he/she has done!

# Before you start

- know your anatomy
- learn surgeon-speak
- get to know the endoscopists, surgeons, and their support staff
- receive the specimen fresh (if possible)
- find out as much as you can about the case
- don’t be coy about asking the surgeon to show you what he/she has done!
- ask yourself “what does the clinician need to know?”

# Before you start

- know your anatomy
- learn surgeon-speak
- get to know the endoscopists, surgeons, and their support staff
- receive the specimen fresh (if possible)
- find out as much as you can about the case
- don’t be coy about asking the surgeon to show you what he/she has done!
- ask yourself “what does the clinician need to know?”
- expect to report the histology yourself

# The specimen

- wash out luminal contents carefully
- think about taking fresh tissue
  - microbiology (esp TB), EM, cytogenetics, biobanking
- consider inflating with formalin & immersing in fixative
  - diverticular disease
  - Crohn's disease
  - stricturing pathology
  - some tumours

# Colorectal cancer – fix open or closed?

**Treat every specimen on its merits**

# Tumours

Decide whether to open the whole specimen along its length or to leave the tumour intact with a ‘wick’ of foam sponge or absorptive paper

- opening may be better in smaller, non-circumferential tumours and after neo-adjuvant therapy
- do so along the normal-appearing anti-mesenteric border
- try to avoid the tumour

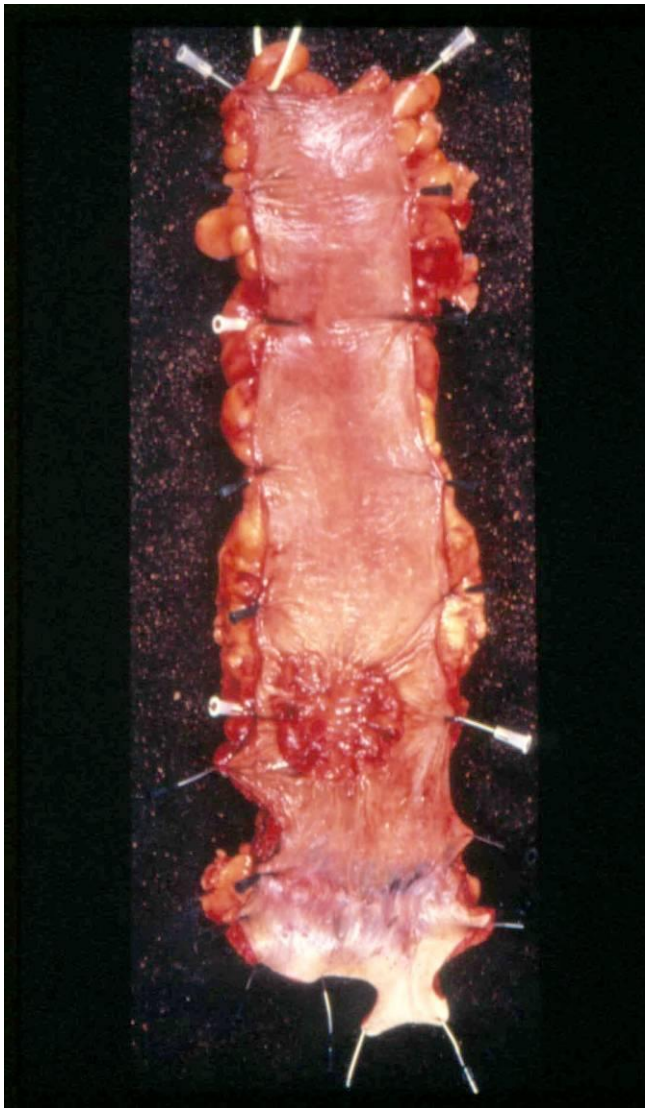

# Tumours

- the circumferential surgical margin is all important, especially in rectal cancer
- longitudinal margins less important – if > 3cms, don’t submit
- don’t submit donuts unless < 3cms
- ‘paint’ the non-peritonealised ‘circumferential’ margin, NOT the serosal surface

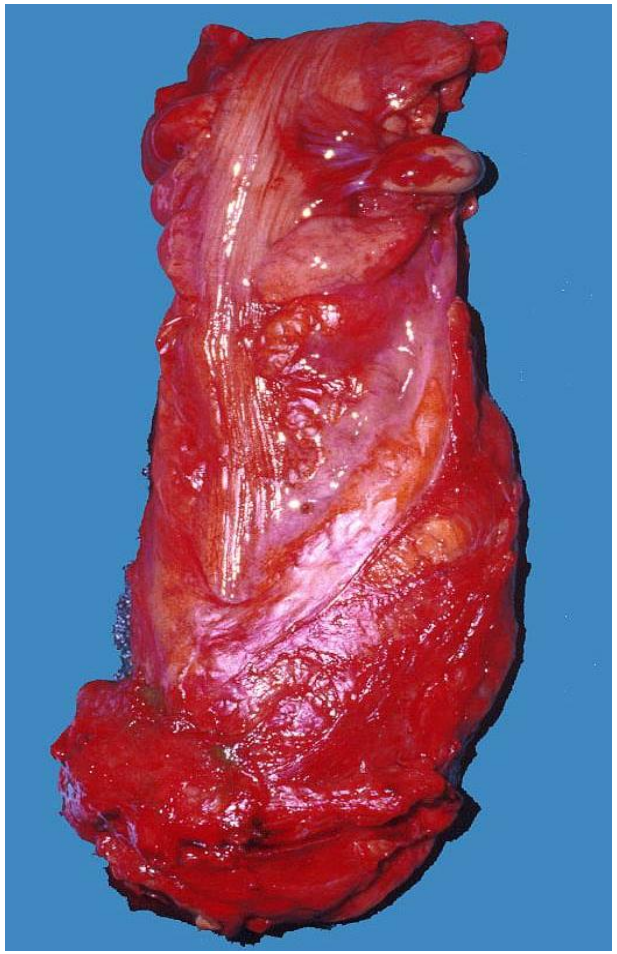

# The problem with paint.....

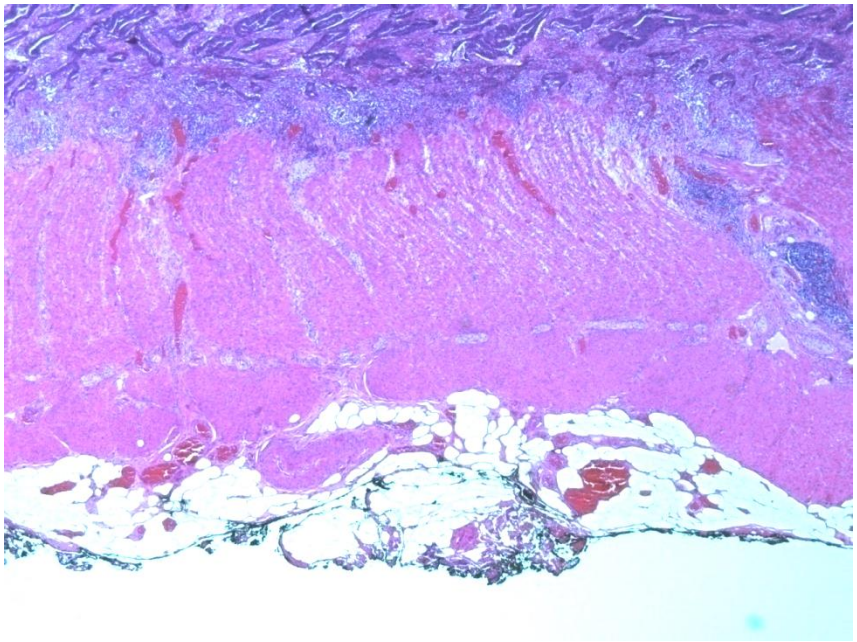

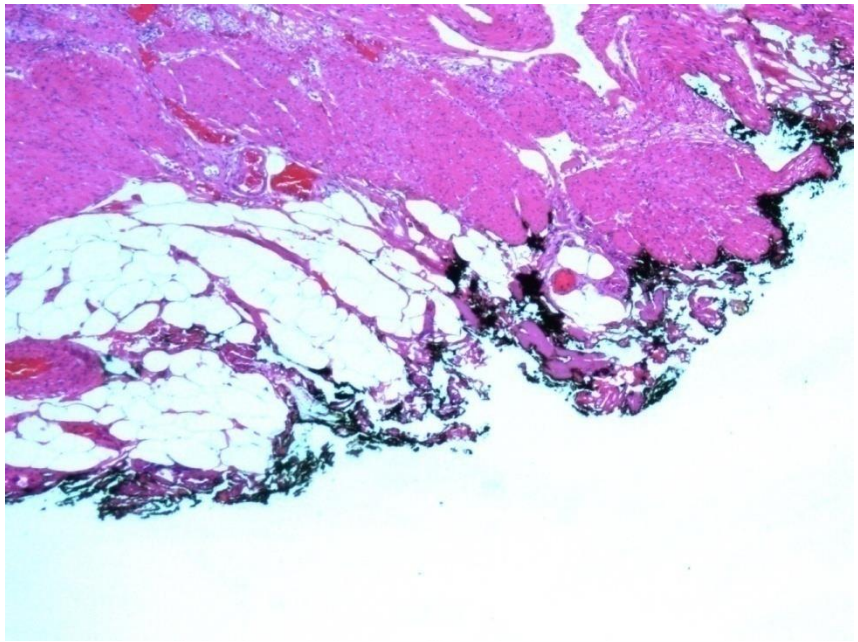

# To paint or not to paint?

"There remains considerable contention about the practice of painting surgical specimens in the GI tract. Indeed we believe that there has been an unfortunate explosion in this practice such that barely a specimen can escape the dissection room without being covered in paints of various colours, often to the detriment of accurate macroscopic pathological assessment. No more so is this apparent, in our view, than in GI cancer specimens.

"We firmly believe that ***only surgical resection margins*** should be painted.

"We advocate the intelligent, thoughtful (and restricted) use of paint on such surgical specimens."

*Ludeman & Shepherd, 2005*

# Good old coloured gelatin....


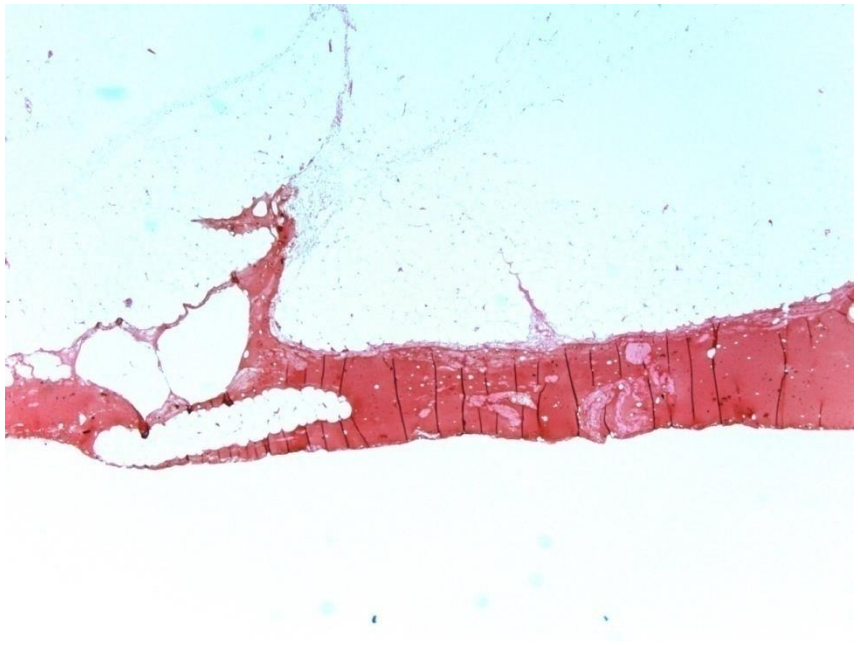

# COLORECTAL CANCER AND THE PERITONEAL SURFACE

# The relationship of the peritoneum to the rectum

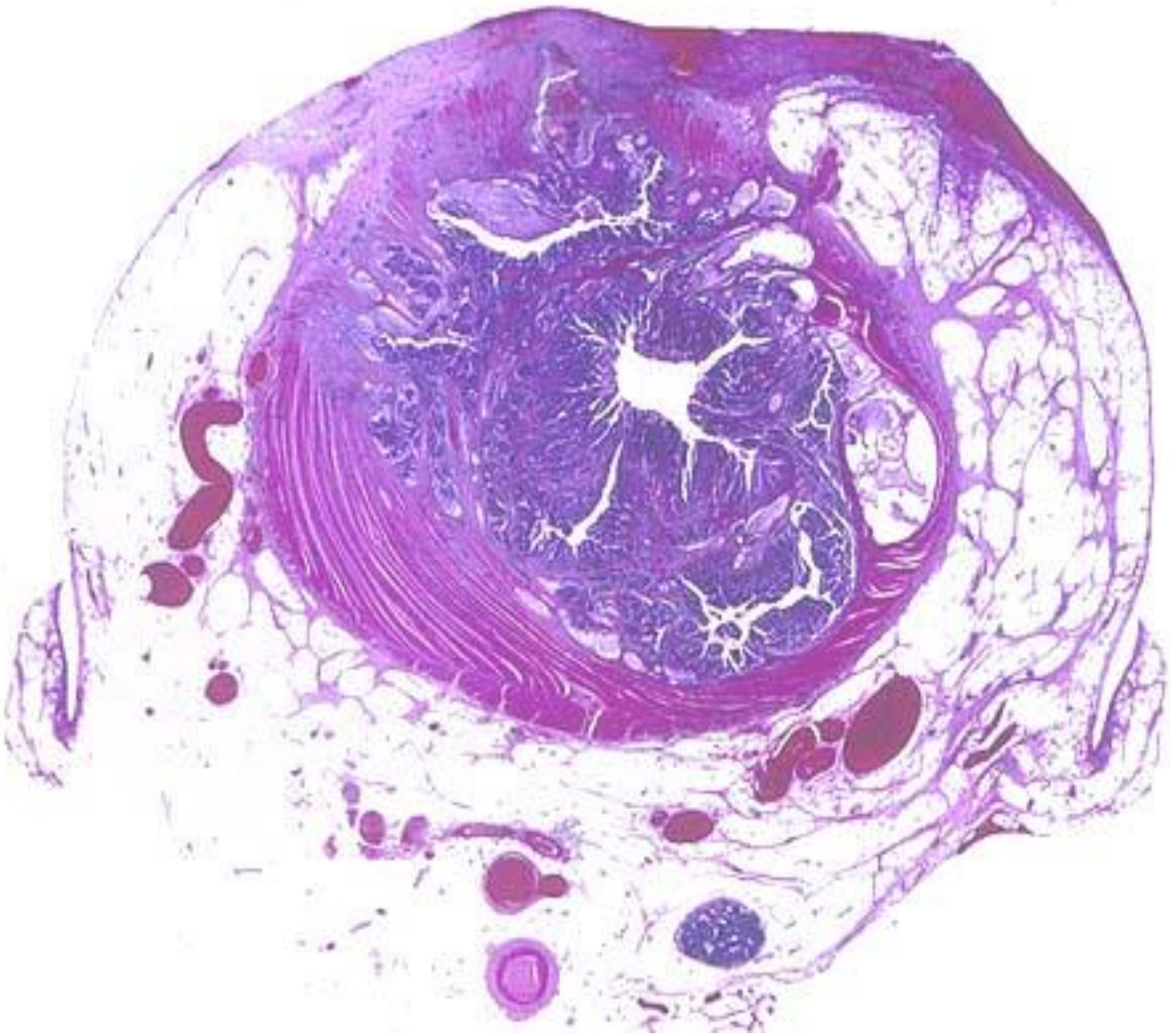

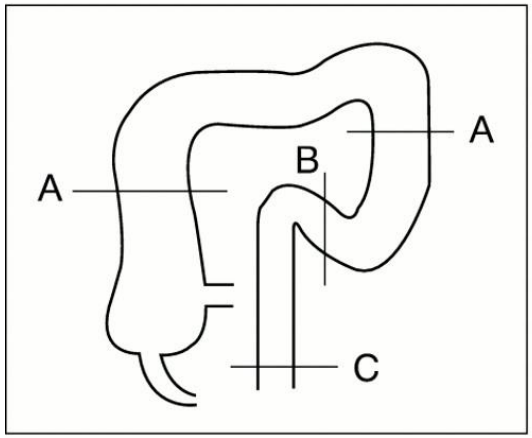
A
B
A
C

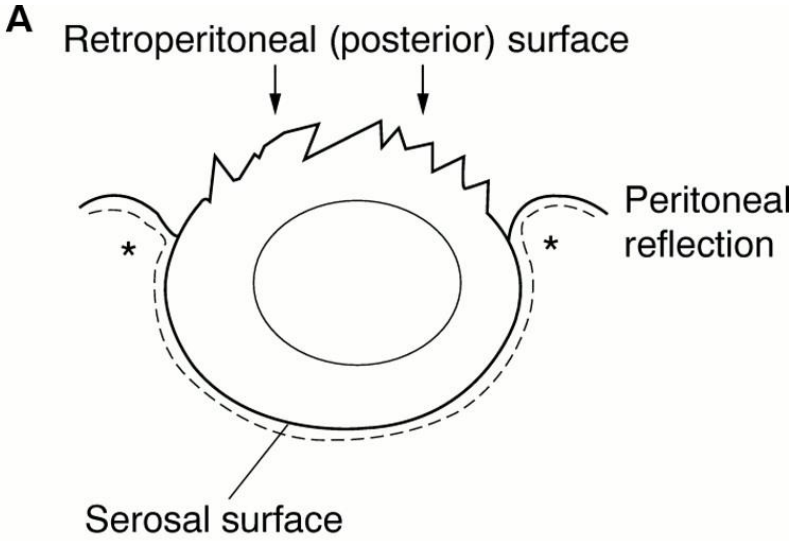
A
Retroperitoneal (posterior) surface
Peritoneal reflection
*
*
Serosal surface

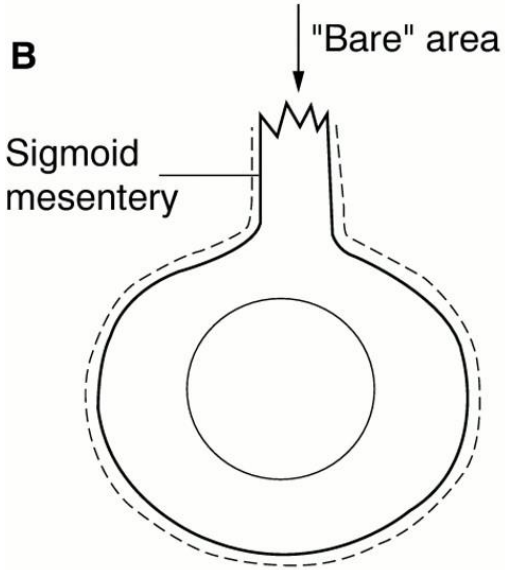
B
"Bare" area
Sigmoid mesentery

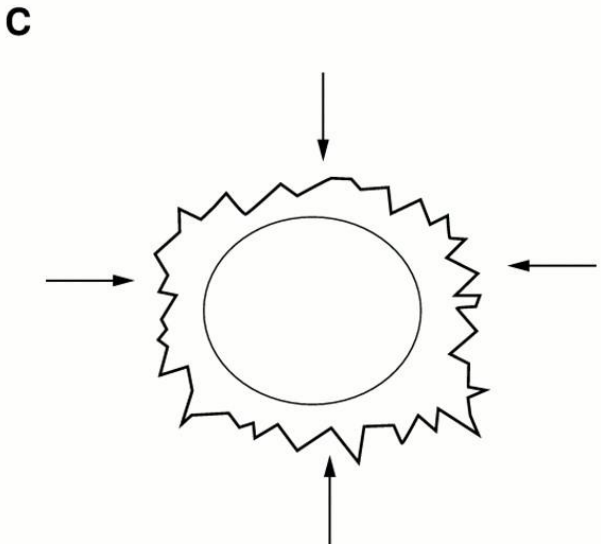
C

# Macroscopic assessment of peritoneal involvement in colorectal cancer

- where does it occur?

  unusual on flat surfaces: much more likely in fat-lined crevices

- how to assess it?

  at least two blocks of most likely areas

  may need levels

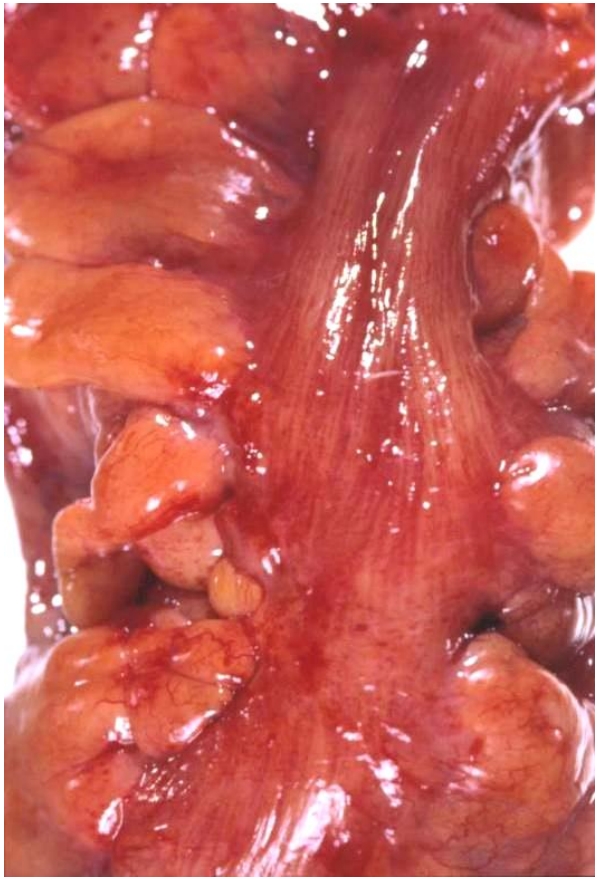

# Peritoneal involvement in colorectal cancer

where does it occur?

- in the crevices…

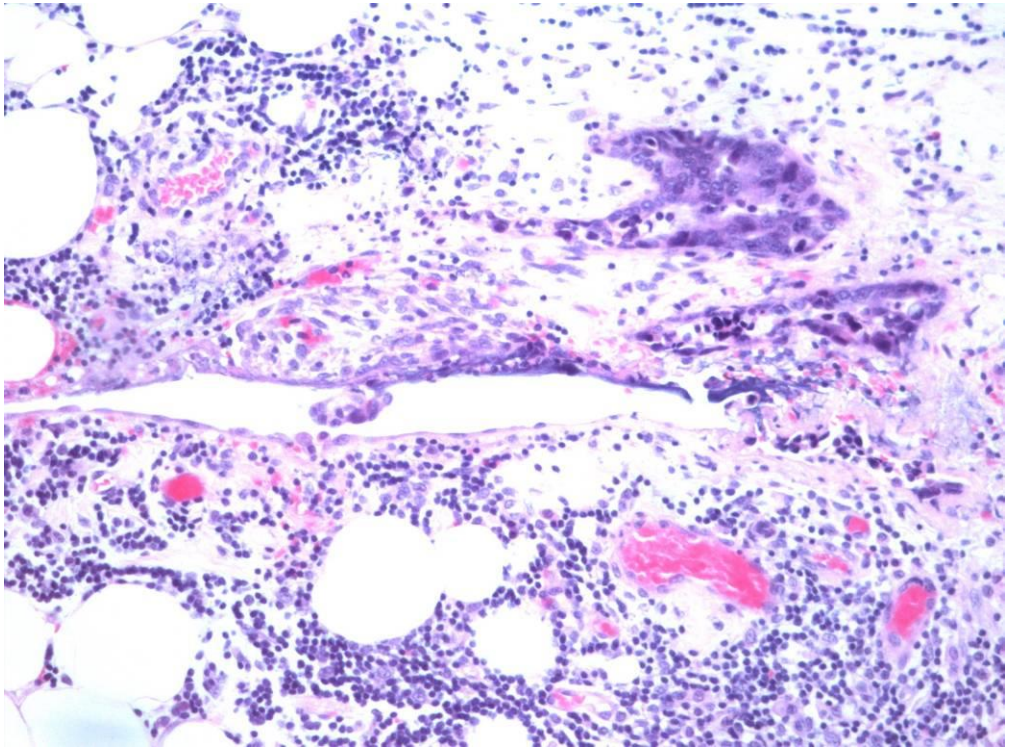

# RCPath datasets & guidelines

- first dataset (P Quirke, GT Williams), 1998
- second revision (GT Williams, P Quirke, NA Shepherd), 2007
- third revision (MB Loughrey, P Quirke, NA Shepherd), 2014
- wide consultation with ACPGBI, NCRI, BSG, BDIAP, NHS Bowel Cancer Screening Pathology Group & the membership of the College
- a long gestation!

# RCPath colorectal cancer dataset, 2nd revision (2007)

## G T Williams, P Quirke, N A Shepherd

*It is therefore recommended that pathologists audit their reports at regular intervals (perhaps yearly) to ensure that their overall results are not significantly different from what might expected. Three standards are recommended for this purpose, namely that in a series of at least 50 resection specimens:*

*a) the median number of lymph nodes examined is 12*

*b) the frequency of serosal involvement is at least 20% for colonic cancers and 10% for rectal cancers*

*c) the frequency of extramural vascular invasion is at least 25%*

*We believe there is a reasonable evidence base to suggest that the mean harvest of lymph nodes should be at least 12 but accept that there is less evidence base for the two other outcome measures. Nevertheless, we believe that this is a start at setting such standards and evidence will follow to allow us to adjust these levels in the future.*

# RCPath colorectal cancer dataset, 3nd revision (2014)

M B Loughrey, P Quirke, N A Shepherd

- The median number of lymph nodes examined should be greater than 12.
- The frequency of serosal involvement should be at least 20% for colonic cancers and 10% for rectal cancers.
- The frequency of venous invasion, including intramural (submucosal and intramuscular) and extramural, should be at least 30%.

*These are minimum standards with many good centres in the UK finding 18 lymph nodes as a median count, 30–40% serosal involvement and venous invasion in over 40% of cases.*

# Gloucestershire BCSP QA visit, October 2013: Colorectal cancer quality standards

| Parameter | median lymph node harvest | PI colon | PI rectum | EMVS |
|---|---|---|---|---|
| Quality standard | 12 or more | > 20% | > 10% | > 25% |
| Pathologist A | 25 | 36% | 14% | 51% |
| Pathologist B | 19 | 49% | 8.3% | 42% |
| Pathologist C | 19 | 33% | 27% | 48% |

# LYMPH NODE HARVESTS

# RCPath colorectal cancer dataset, 3nd revision (2014)

M B Loughrey, P Quirke, N A Shepherd

- The median number of lymph nodes examined should be greater than 12.
- The frequency of serosal involvement should be at least 20% for colonic cancers and 10% for rectal cancers.
- The frequency of venous invasion, including intramural (submucosal and intramuscular) and extramural, should be at least 30%.

*These are minimum standards with many good centres in the UK finding 18 lymph nodes as a median count, 30–40% serosal involvement and venous invasion in over 40% of cases.*

# The influence of the number of lymph nodes on the proportion of involved nodes in rectal cancer


*Hermanek et al, 1993*

# Influence of number of nodes on pN status: South & West colorectal cancer LN audit

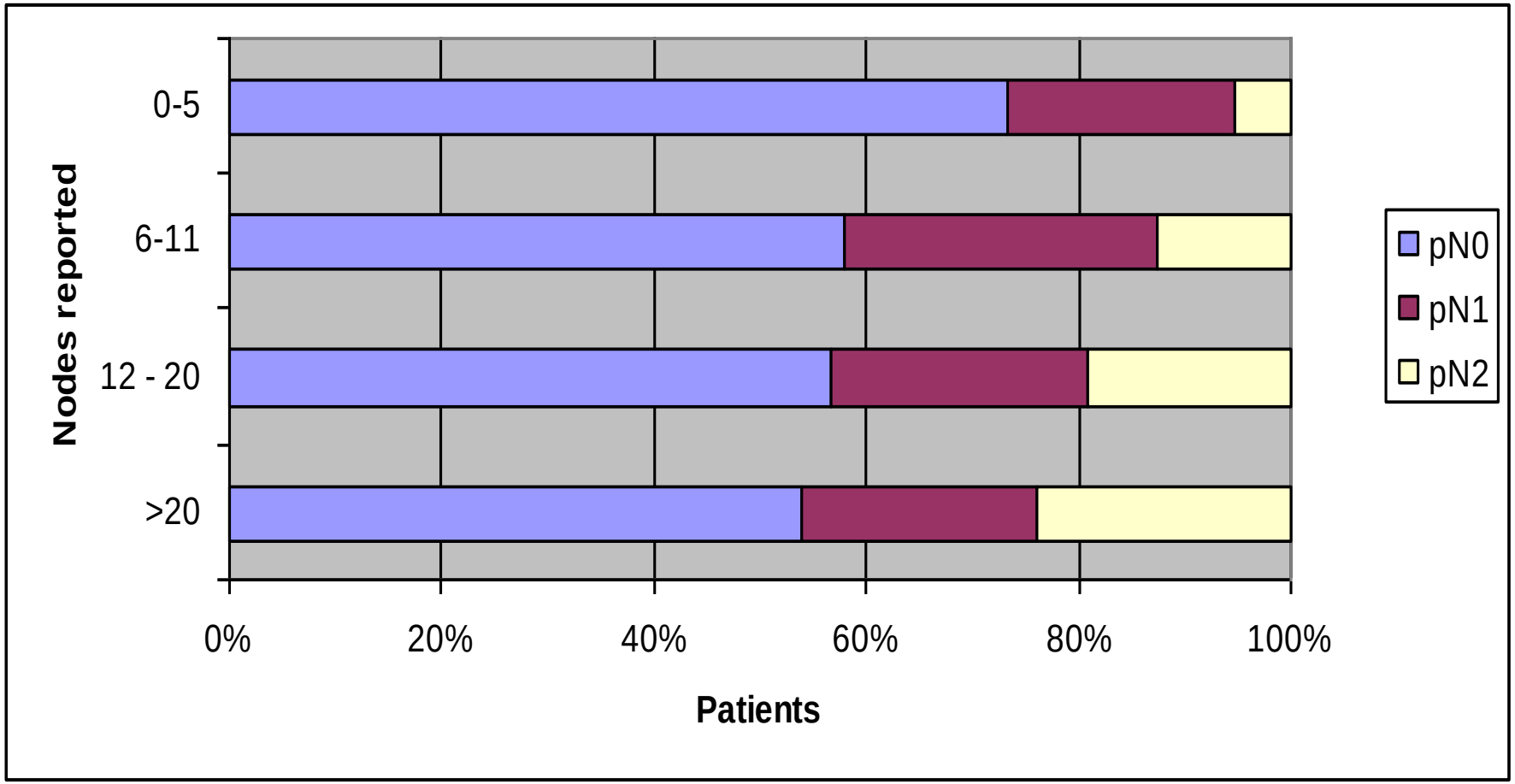


*Weekes & Shepherd, 2007*

# Influence of neo-adjuvant therapy on rectal LN harvest

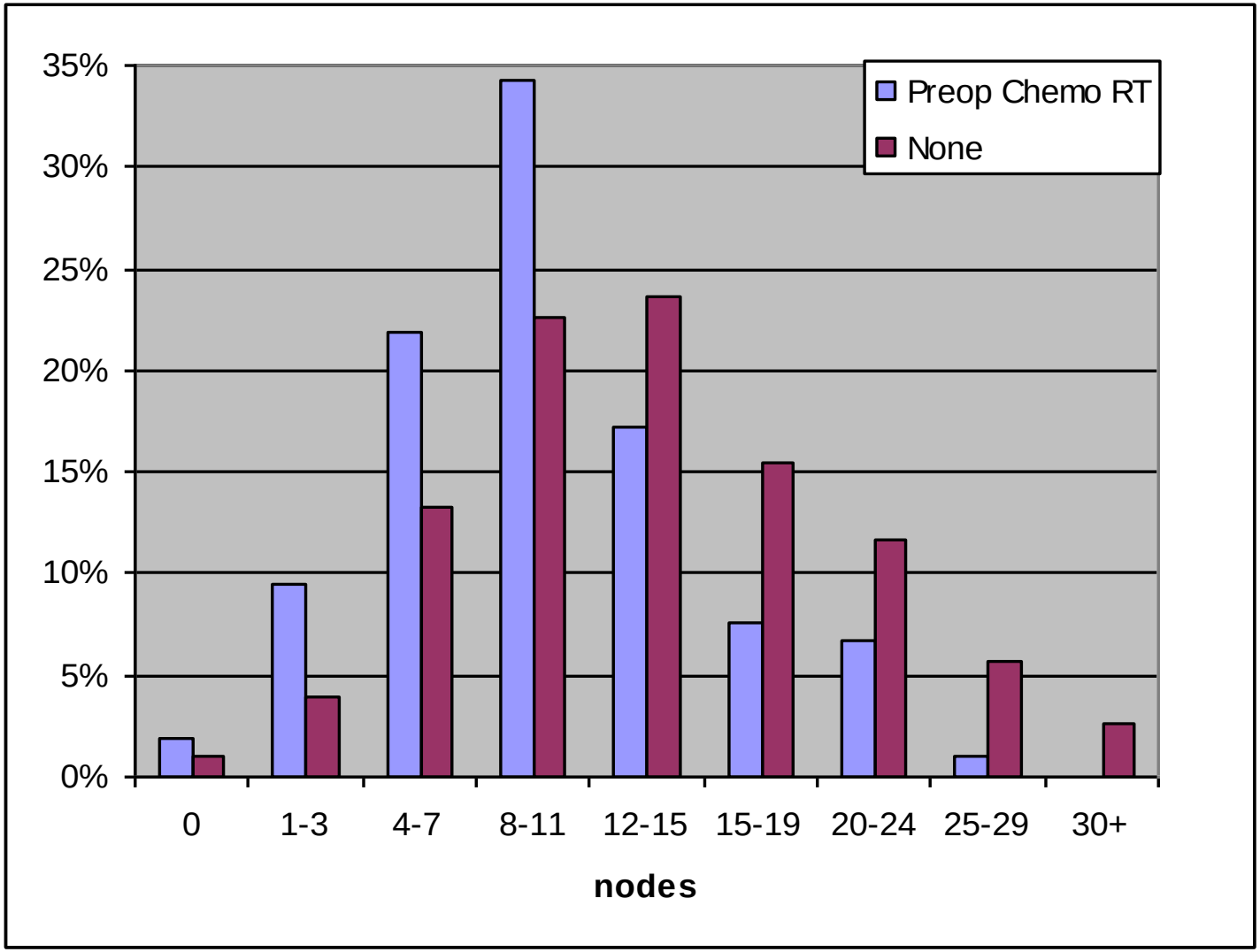


*Weekes & Shepherd, 2007*

# What can we do to improve?

- time and motivation of pathologists and/or dissecting BMSs
- methods to improve identification of nodes:

  fat clearance

  tattooing

  intra-arterial injection

# Postoperative intra-arterial methylene blue injection of colorectal cancer specimens increases the number of lymph nodes recovered

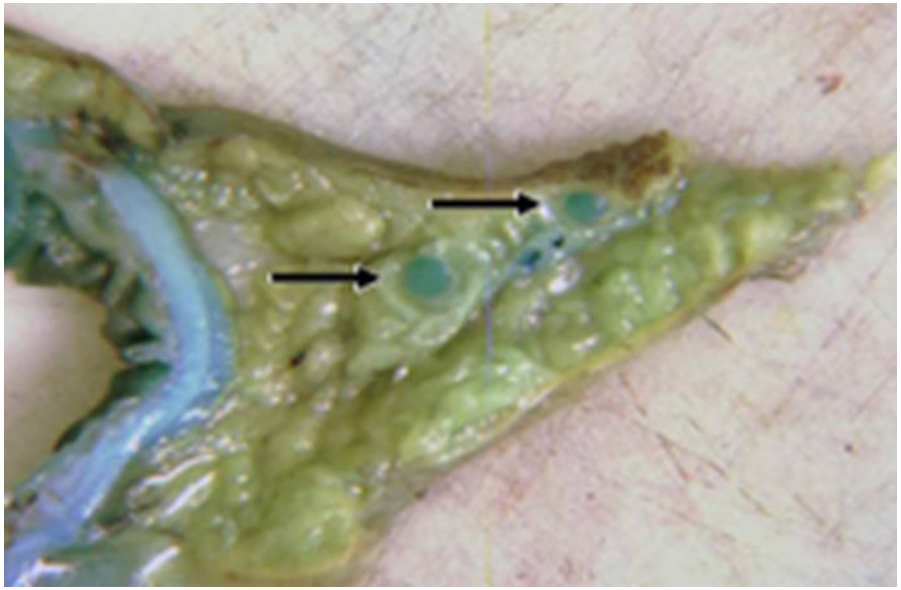

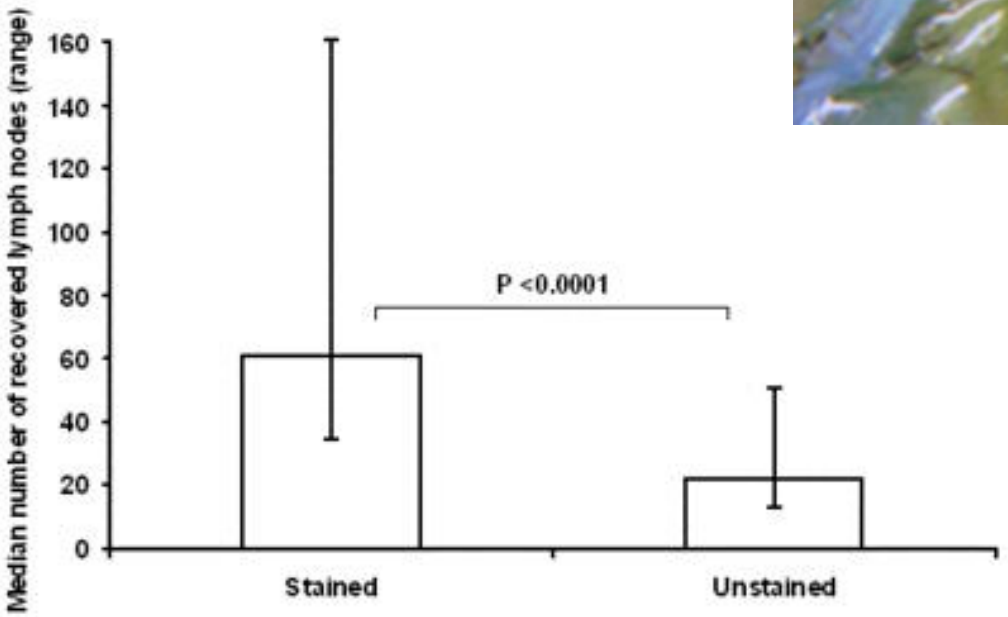


*Tornroos et al, 2011*

# What can we do to improve?

- time and motivation of pathologists and/or dissecting BMSs
- methods to improve identification of nodes:

  fat clearance

  tattooing

  intra-arterial injection
- if your rates are low…….

# Lymph node harvests in colorectal cancer

- lymph node involvement (hence numbers) is the most important determinant of the decision to institute adjuvant therapy
- lymph node numbers themselves are prognostically informative
- be suspicious when you see the word ‘sample’
- UK pathologists are now all being assessed using this simple and readily auditable parameter



# Pathologists assessing the quality o rectal surgery

muscular plane

(1 or poor)

Poor bulk to mesorectum with defects down to muscularis propria and/or very irregular CRM

intramesorectal plane

(2 or moderate)

Moderate bulk to mesorectum but irregularity of mesorectal surface. Moderate coning of the specimen toward distal margin. At not site is MP visible except at the levator insertion. Moderate irregularity of CRM

mesorectal

(3 or good)

Intact mesorectum with only minor irregularities of the smooth mesorectal surface. No defect deeper than 5mm. No coning at distal margin. Smooth CRM on sectioning.

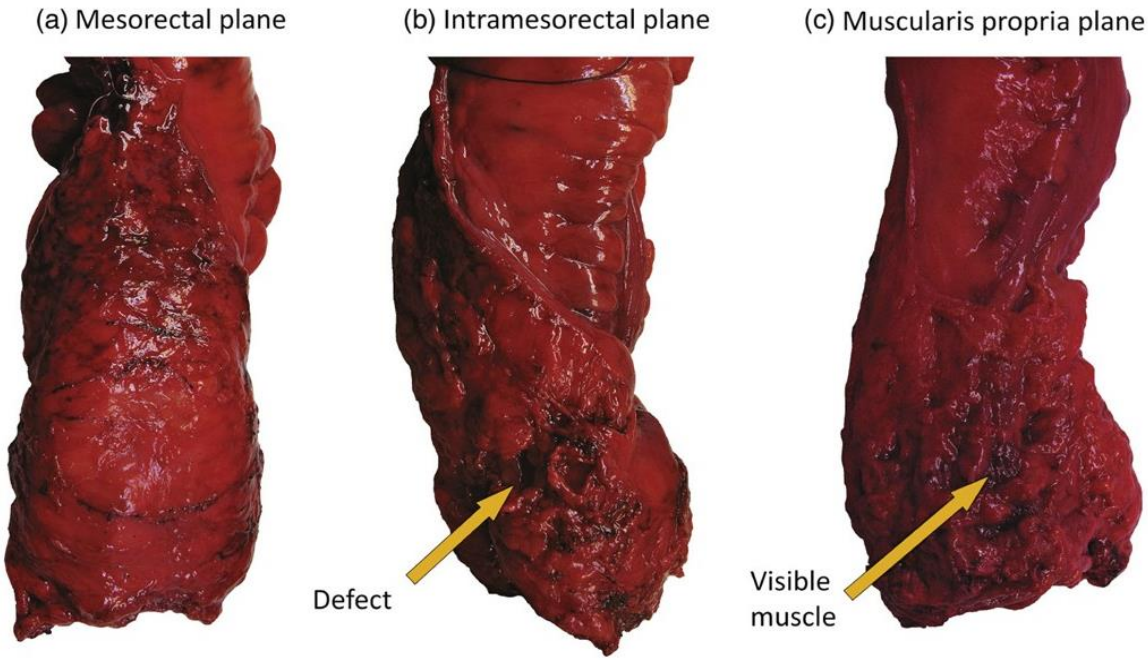


**Figure 32.3** Grading the plane of surgery for the mesorectum: note the intact mesorectal envelope lined by shiny mesorectal fascia in the mesorectal plane (a); significant defects should be graded as intra-mesorectal (b) or muscularis propria (c) if they extend down to the muscle layer.

*Morson and Dawson's Gastrointestinal Pathology*, Fifth Edition. Edited by Neil A. Shepherd, Bryan F. Warren, Geraint T. Williams, Joel K. Greenson, Gregory Y. Lauwers and Marco R. Novelli.

# MRC CRO7: *Sebag-Montefiore et al, 2008*

| plane by pathology | pre-operative DXR | selected post-operative DXR based on CRM positivity | total |
|---|---|---|---|
| muscular plane (1 or poor) | 9.0% | 18.7% | 14.0% |
| intramesorectal plane (2 or moderate) | 4.5% | 11.0% | 7.8% |
| mesorectal plane (3 or good) | 1.3% | 6.1% | 3.7% |

figures are 3 year local recurrence rates

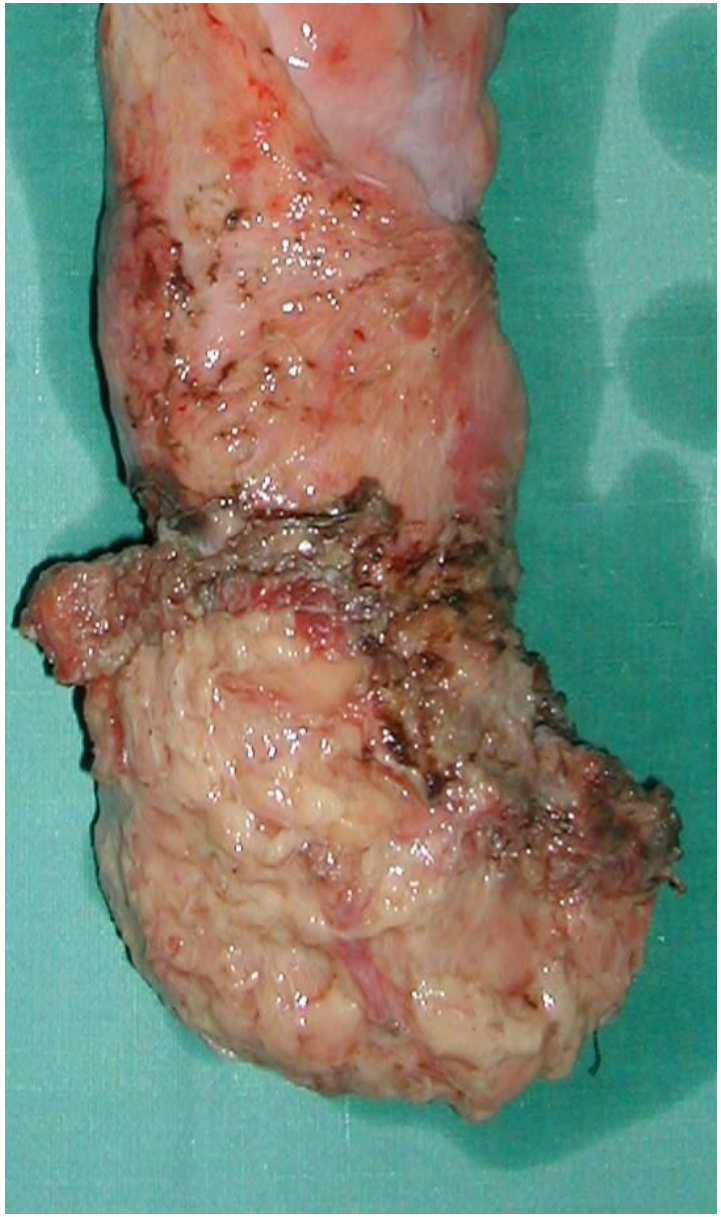

# APR specimens

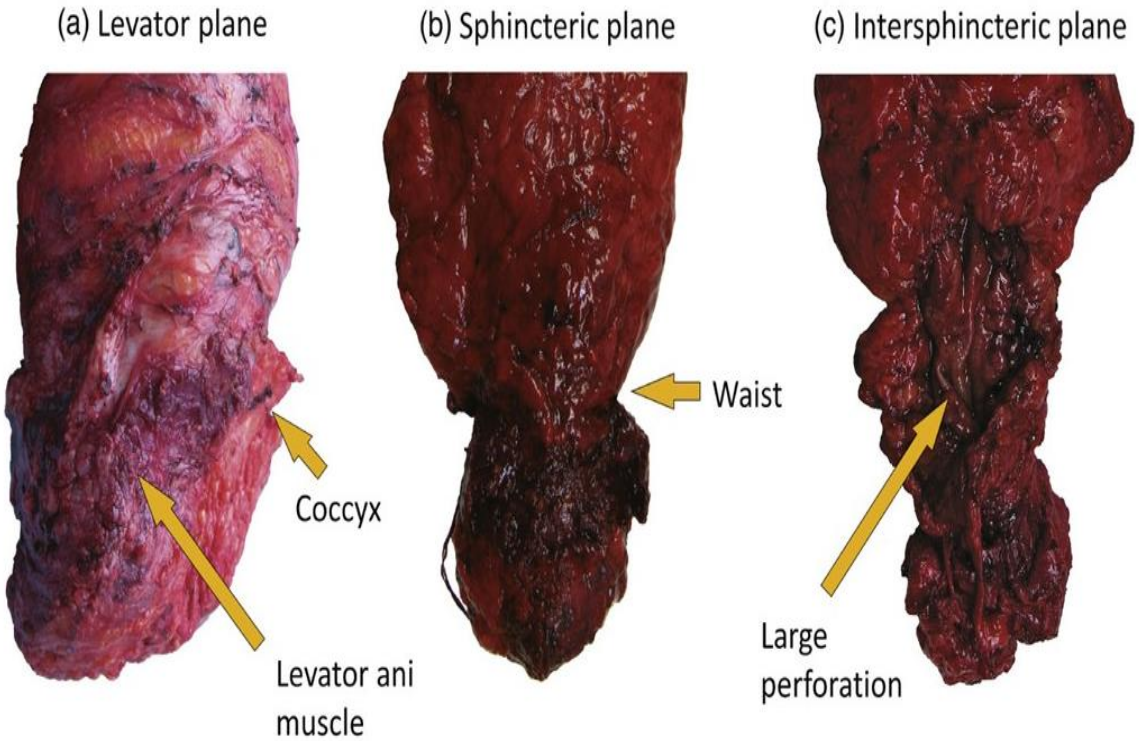


**Figure 32.4** Grading the plane of surgery around the anal sphincters in abdomino-perineal excisions of the rectum and anus. (a) Note the adherent levator muscle in the levator excision that prevents the waisting seen (b) when following the sphincteric plane. (c) Any defects into the sphincter muscles, submucosa or lumen should be classed as an intersphincteric excision.

*Morson and Dawson's Gastrointestinal Pathology*, Fifth Edition. Edited by Neil A. Shepherd, Bryan F. Warren, Geraint T. Williams, Joel K. Greenson, Gregory Y. Lauwers and Marco R. Novelli.

# How many blocks?

- Tumour blocks (4-6) to allow assessment of
  - histological type and differentiation
  - extramural spread and its extent in mm
  - tumour closest to serosal surface (NB crevices)
  - tumour in relation to non-peritonealised CRM (especially anteriorly in the rectum)
  - extramural venous invasion
  - involvement of adjacent organs

# Standardise descriptions and block-taking

A right hemicolectomy specimen consisting of 47mm of terminal ileum, caecum with a 58mm appendix and 138mm of proximal colon. Although the ileo-caecal valve appears moderately prominent diffusely, suggesting lipo-hyperplasia, there is also a localised fatty nodule 11mm in diameter on the supero-posterior aspect of the valve, suggesting a lipoma. In the caecum is a polypoid tumour 34mm in axial length and 42mm in transverse diameter. There are no other polyps or tumours.

NOT 200mm of bowel.....

- standardised block-taking can abrogate the need for block keys (eg appendix, gall bladder, standard cancer resections)

# Introduction of BMS (technician) cut-up

- the vast majority of UK consultant histopathologists support biomedical scientist (BMS) cut-up to some degree
- utilisation of BMS cut-up is rather limited and patchy at present. Reasons cited are cost, staffing levels and concerns related to quality and boundaries of staff roles, effect on medical trainees
- further measures taken by the Institute for Biomedical Sciences and RCPath to extend training and examination of BMS cut-up to include more complex specimens will help provide assurance on quality and standards

# Audit of enhanced BMS cut-up role in colorectal cancer reporting

DSA Sanders, AP Smith, RA Carr, SE Roberts, S Gurusamy, EJV Simmons

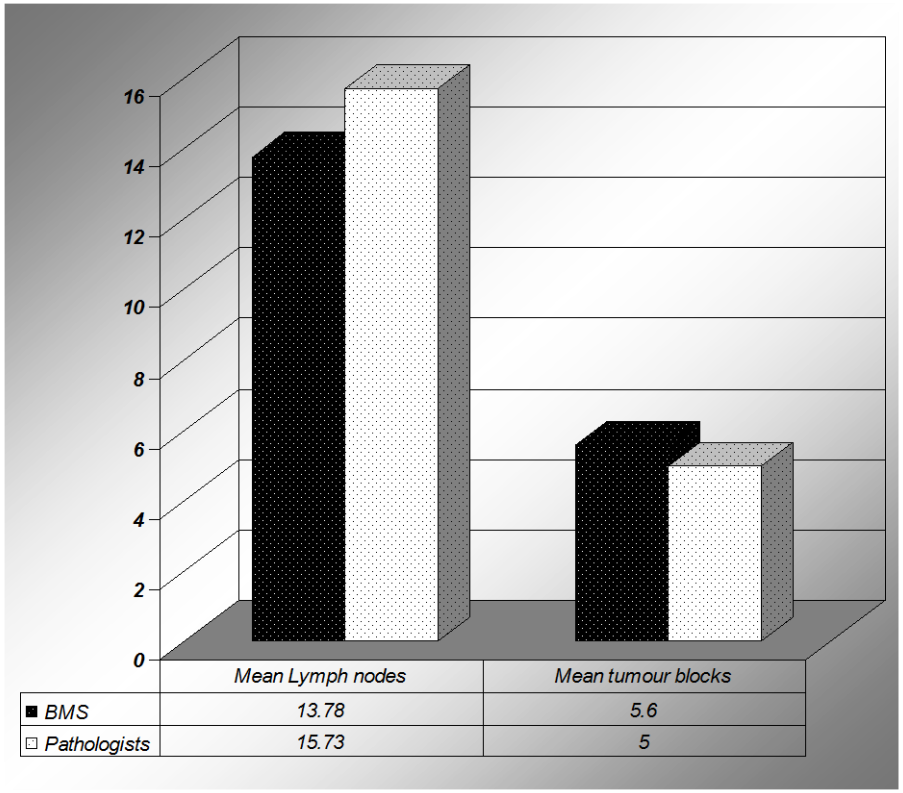


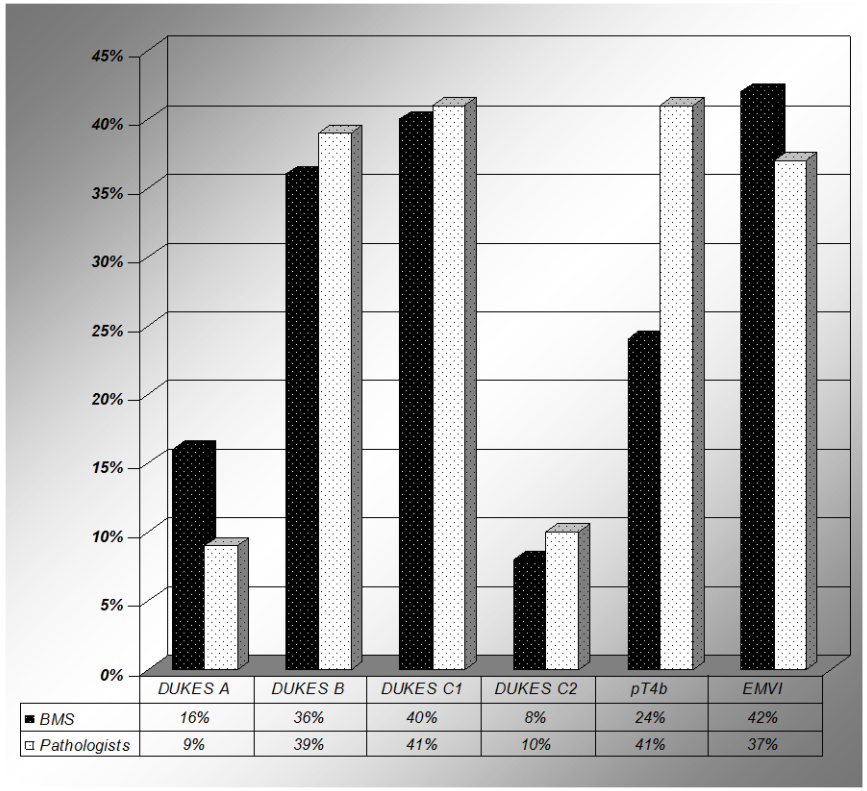

# After the cut-up is done, what evidence is there of its efficacy?

- Quality of macroscopic description
  - digital dictation
  - standard dictation
  - scribe and dictate at the time of final report
- Quality is all important
  - don’t show anatomical and surgical ignorance
  - standardise descriptions
  - may abrogate the need for tedious block keys:

*Gall bladder: A = fundus and cystic duct margin; B = cross section of body*

*Appendix: A = LS of tip and XS of base margin; B = cross sections of ‘body’*

- Photography
  - standard for many cancers, TEMS, trials e.g Foxtrot
  - useful for certain diseases, eg CIBD



**H J R ‘Dick’ Bussey, St Mark’s Hospital, London, 1936**

# What we will consider in the ‘lower GI’ tract

Resection specimens

Polyps and local resections

Inflammatory conditions

Other benign pathologies

# Local excisions

- polypectomy
- endoscopic mucosal resections
- transanal endoscopic microsurgical excision of rectal tumours (TEMS)

# Local excisions

- orientation is vital
- embed the whole of the lesion to allow assessment of margins
- work with endoscopic & surgical colleagues and their staff to obtain properly presented specimens

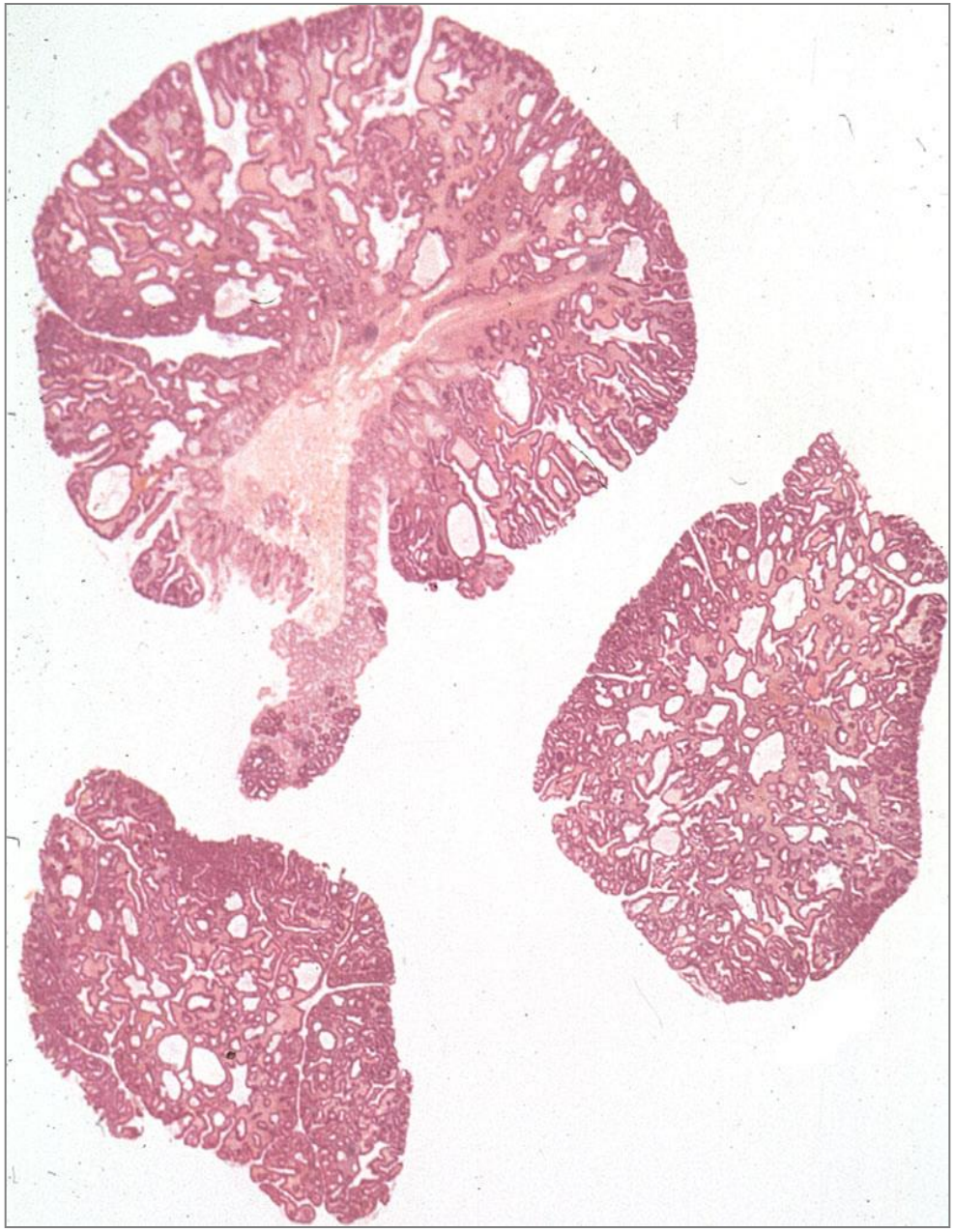

# Polyp measurement in BCSP
## Terminal digit preference

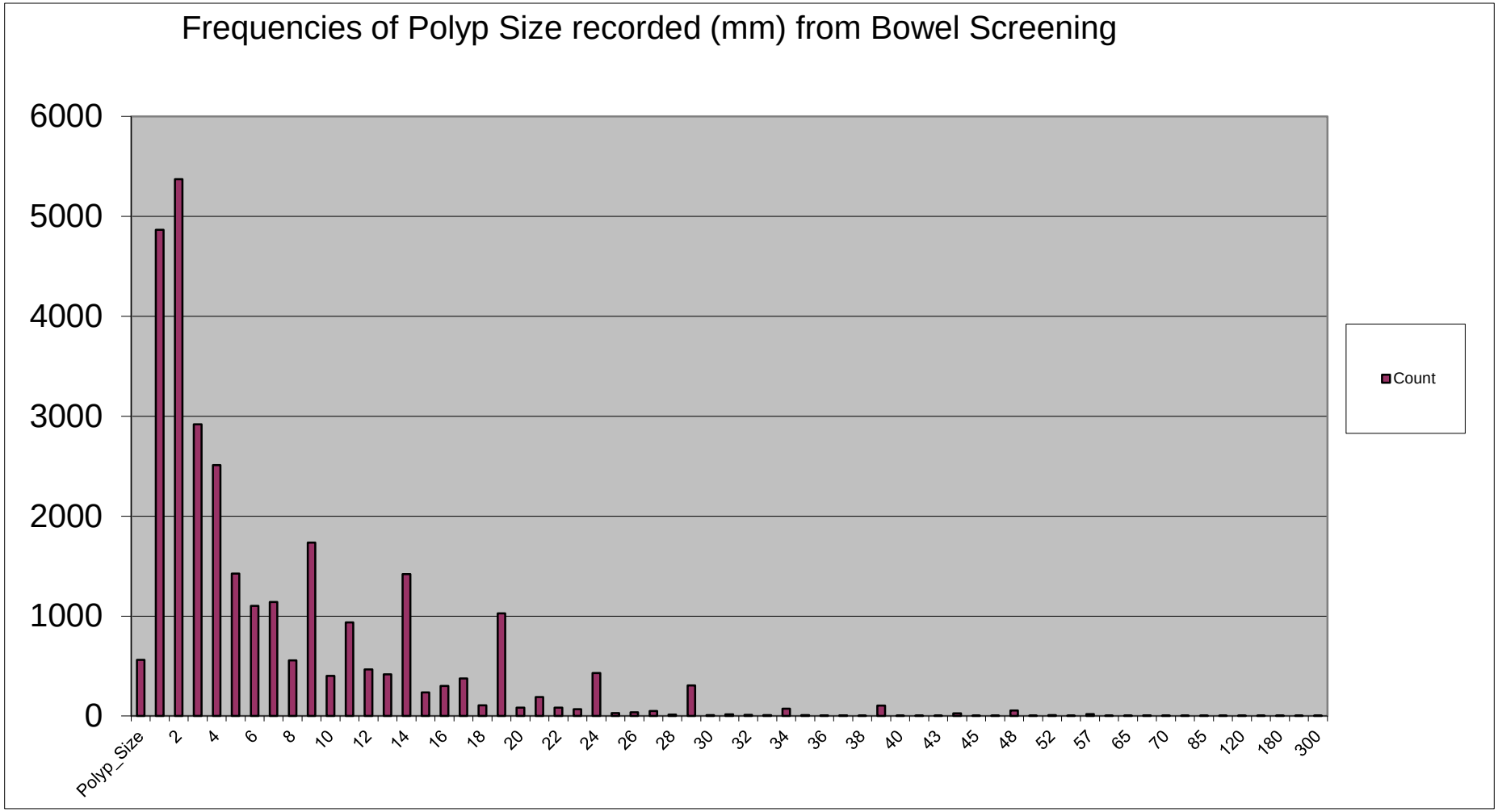

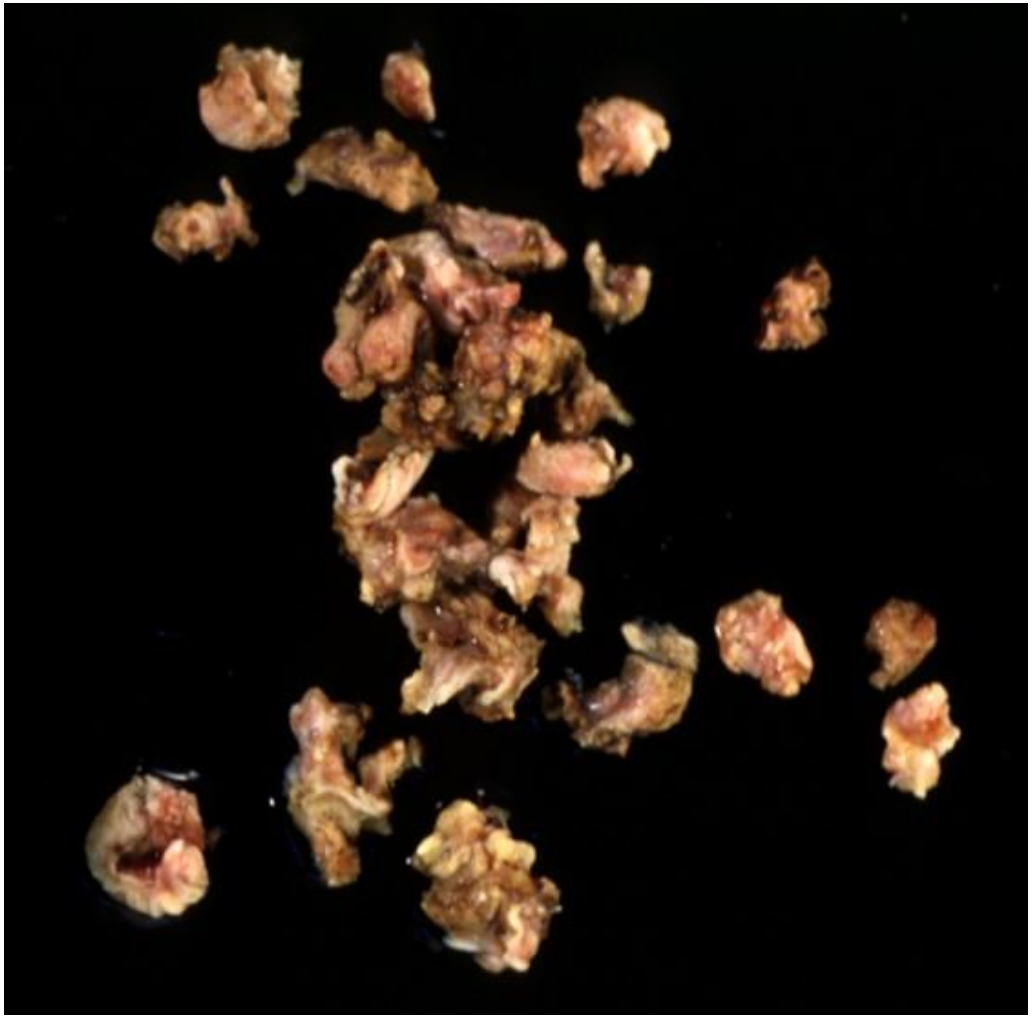

**TART…..**

# TEMS

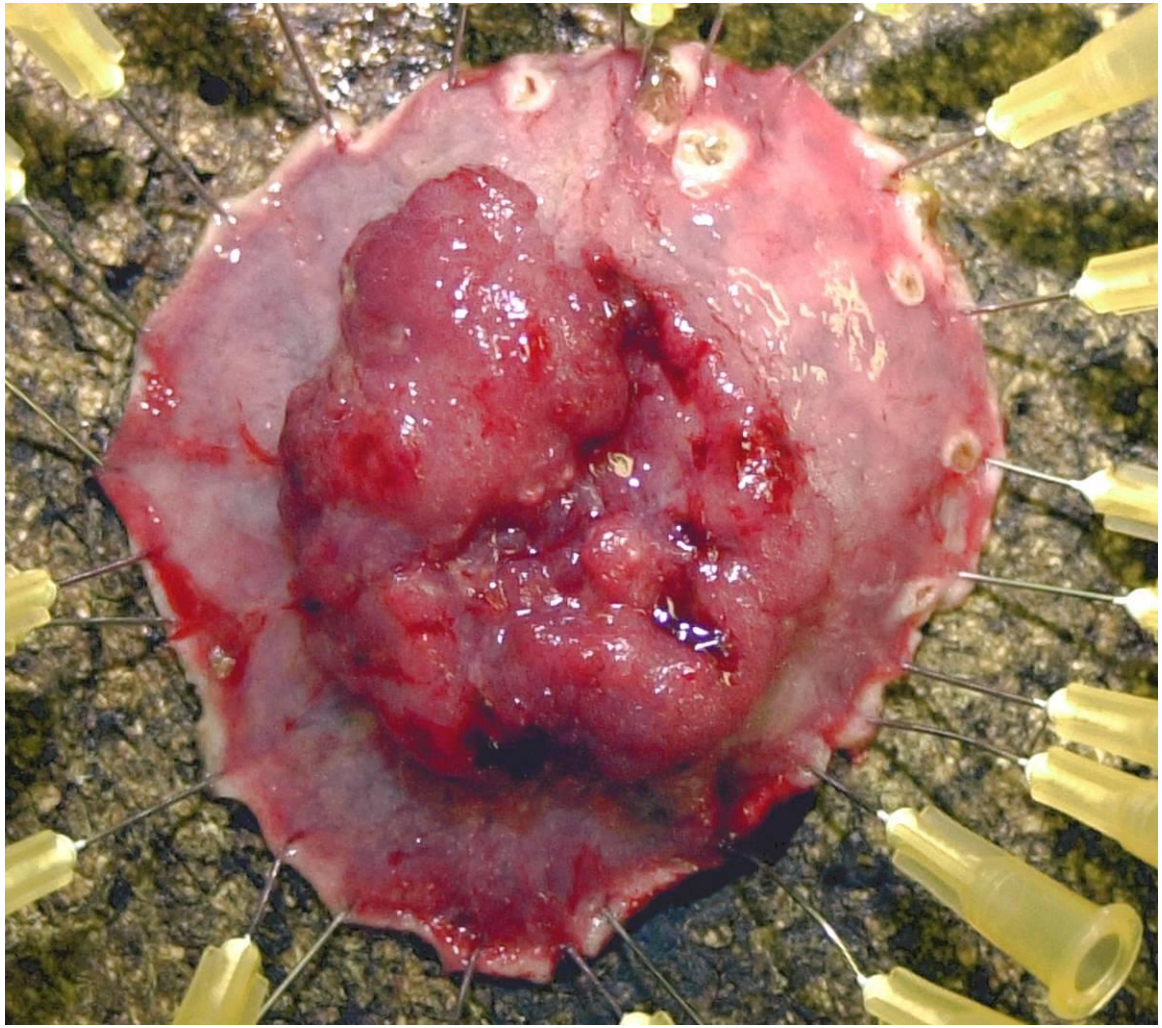

# A rectal TEMS

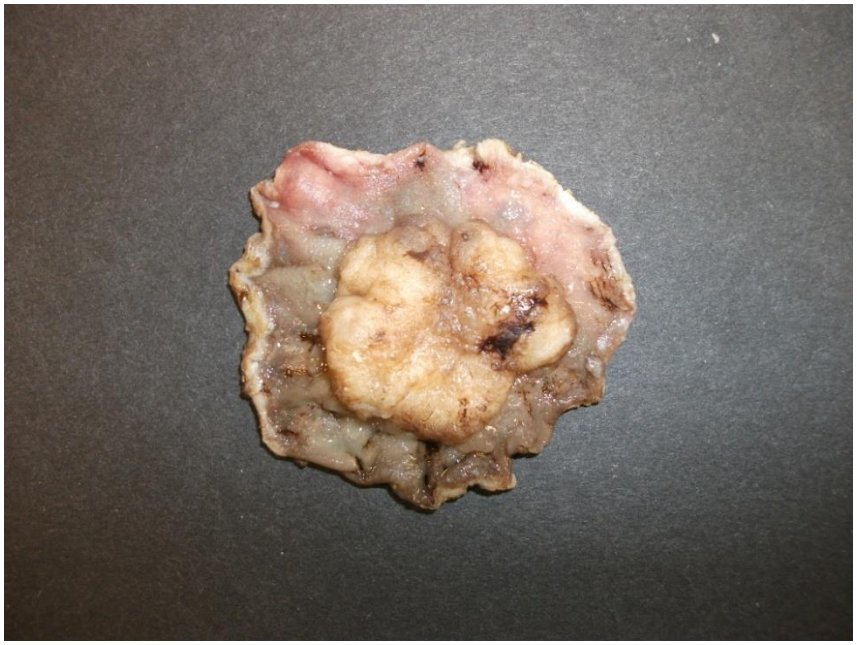

# A rectal TEMS: economy of blocks (and work for BMSs and you!)

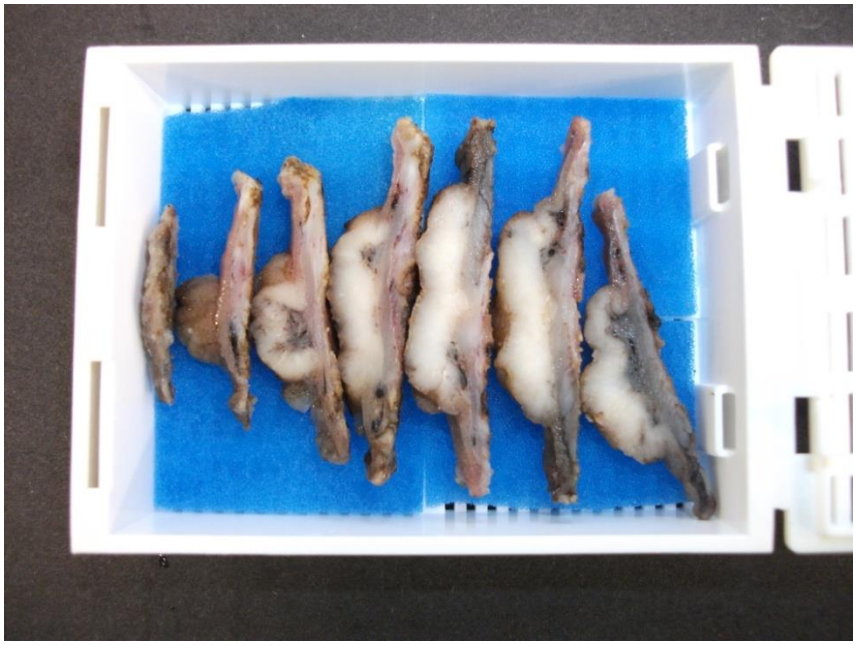

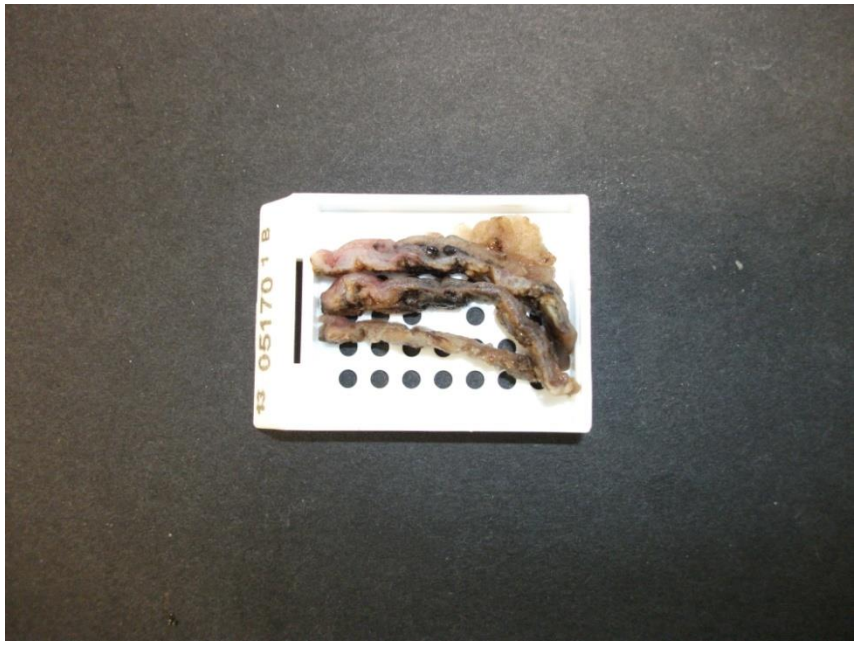

# What we will consider in the ‘lower GI’ tract

Resection specimens
Polyps and local resections

Inflammatory conditions

Other benign pathologies

# Inflammatory bowel disease

- macroscopic pathology is just as important as microscopic pathology to differentiate UC, CD and indeterminate colitis

**Table 35.1** Macroscopic differences in the pathology of ulcerative colitis and Crohn's disease in the large intestine

| Ulcerative colitis | Crohn's disease |
|---|---|
| Disease in continuity | Disease usually discontinuous |
| Rectum almost always involved | Rectum normal in 50% |
| Terminal ileum involved in 10% | Terminal ileum involved in 30% |
| Granular and ulcerated mucosa (no fissuring) | Discretely ulcerated mucosa; cobblestone appearance; fissuring |
| Often intensely vascular | Vascularity seldom intense |
| Normal serosa (except in acute fulminating colitis) | Serositis common |
| Muscular shortening of colon; fibrous strictures very rare | Shortening due to fibrosis; fibrous strictures common |
| Never internal spontaneous fistulae | Enterocutaneous or intestinal fistulae in 10% |
| Inflammatory polyposis common and extensive | Inflammatory polyposis less prominent and less extensive |
| Dysplasia and malignant change well recognised | Malignant change possibly less common |
| Anal lesions in less than 25%; acute fissures, excoriation and oedematous anal tags less common | Anal lesions in 75%; anal fistulae (often multiple); anal ulceration |

# Fat-wrapping in Crohn’s disease

# Ulcerative colitis

- ‘Ulcerative colitis goes up to where it stops’

*The late Professor Bryan Warren*

- the caecal patch lesion of UC

# Indeterminate colitis

- diagnosis made only in resection specimens (not biopsies)
- 10-20% of colectomies, especially ‘fulminant’ colitis
- some features of UC and Crohn’s
- generally behave as UC
- cautious positive approach to pouch surgery

# What we will consider in the ‘lower GI’ tract

Resection specimens
Polyps and local resections

Inflammatory conditions

Other benign pathologies

# Case study

- 42F. Right oophorectomy for endometriotic cystic mass. Difficult surgery with adhesions
- ’well’ post-op but complained of abdominal pain with vomiting on day 3
- clinical diagnosis of bowel injury/bowel obstruction. Conservative treatment
- day 4 – severe abdominal pain, pyrexia, abdominal distension and vomiting. Mild diffuse abdominal tenderness with rebound and reduced bowel sounds.
- day 5 - guarding in the left iliac fossa with diffuse abdominal pain.
- day 5: laparotomy - sero-sanguinous fluid in the pelvis, no contamination of the abdominal cavity with faeces or with small bowel content. No adherent bowel. Small and large bowel intact.

# Case study

Abdominal X-ray at day 3

# Case study

- day 6: more unwell with deteriorating respiratory function. Admitted to ICU, intubated and ventilated. Signs of systemic sepsis
- abdominal US: colon fluid-filled & dilated (caecum 8.5cms in diameter)
- day 11: - free subdiaphragmatic air. Laparotomy: free gas with faecal contamination through a perforation of the ascending colon
- right hemicolectomy

# Coloproctological surgical & gynaecological experts for plaintiff

- unequivocal bowel injury during initial gynaecological surgery
- negligent failure to detect bowel injury and its effects and to treat early
- major and long term problems for plaintiff because of these failures

# Macroscopic pathology

- marked dilatation of colon (TC 110mm & AC 130mm)
- three longitudinal ulcer tracks in TC along taeniae
- extensive dark granular area in AC and caecum with discontinuous ulcers, mainly on lateral aspects
- ulcers in the caecum and on ICV
- perforated ulcers in caecum and AC (lateral wall)

# Case study

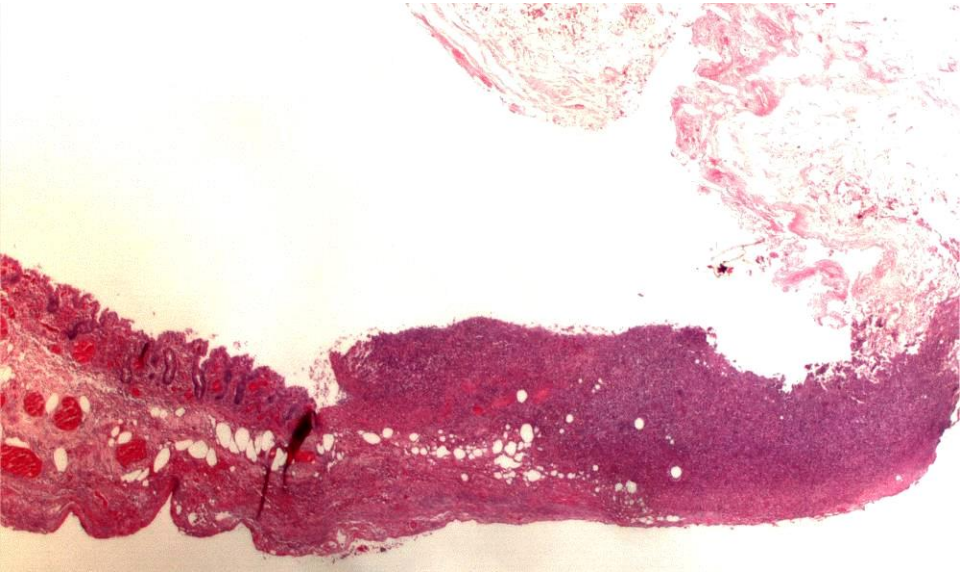

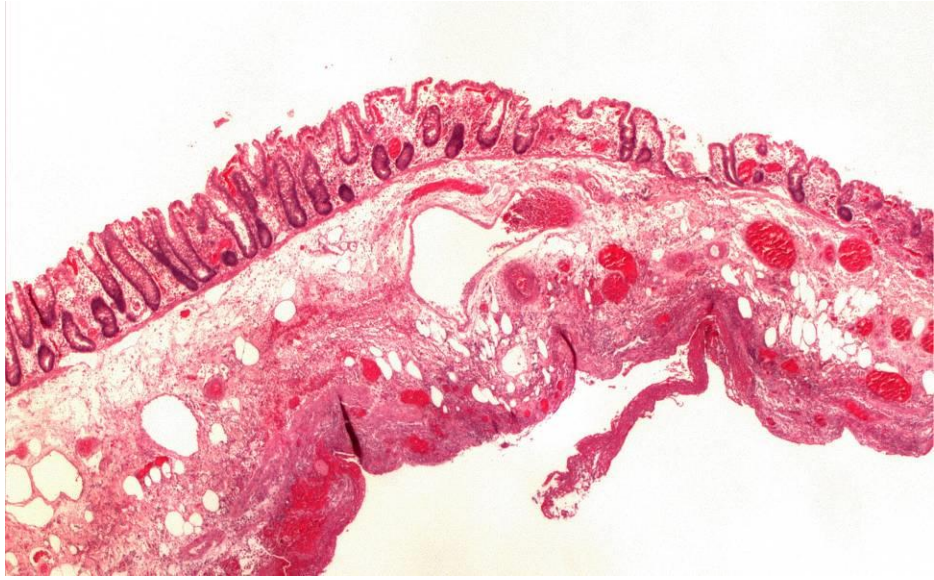

Ischaemic changes extending away from sites of perforations with attenuated bowel wall throughout proximal colon: not suggestive of direct bowel injury

# Ogilvie's syndrome

- named for Sir William Heneage Ogilvie, UK physician: *Ogilvie, H. Large-intestine colic due to sympathetic deprivation: a new clinical syndrome. Br Med J 1948; 2:671-673.*
- classically in pregnancy or after Caesarean section
- malignancy especially multiple myeloma, small cell carcinoma, lymphoma and leukaemia
- after abdominal operations including simpler operations like hernias
- after orthopaedic operations, especially on the hip
- drugs
- treatment – neostigmine but surgery required if perforation is likely (depends on caecal diameter). Decompression caecostomy is another surgical option.
- colonic pseudo-obstruction with dilatation, 'obstructive colitis', caecal and AC ischaemic change, ulceration and perforation

# Case study: learning points

- this case demanded accurate correlation of macroscopic and microscopic pathological findings with clinical data, radiology and findings at the time of the second surgery
- it showed the classical pathological features of Ogilvie's syndrome/pseudo-obstruction with classical pathology
- this is not so very uncommon
- plaintiff's QC and solicitors dropped case after 'expert' pathological review

# Post-operative resections

- it’s easy to jump to the wrong conclusions in post-operative cases
- poor pathological assessment may corroborate those wrong conclusions
- post-surgical/ischaemic pathology may seem tedious and uninteresting but it may be of supreme interest to Trust lawyers, Finance Directors, Queen’s Counsels and judges
- give it the macroscopic, microscopic and clinical correlative attention it deserves

# Intestinal resections for ischaemia

- for the same reasons, please take these seriously
- our job is to confirm ischaemic change but also determine the cause of the ischaemia:
  - mechanical
  - arterial
  - venous
  - vasculitis
  - obscure vascular pathologies
- assessment of margins, the interface of ‘normal’ & ischaemic macroscopically and frank infarcted segments
- AND the mesentery – multiple transverse blocks, including surgical tie-offs

# Take home messages

- appropriate receipt, preparation, photography and macroscopic dissection of specimens are critical for accurate intestinal pathological practice
- the quality of pathology is all important in colorectal cancer management
- the macroscopic assessment of CRC is just as important as the microscopic analysis
- pathologists are being assessed by standards in CRC reporting and two of these are strongly influenced by the macroscopic assessment
- the differential diagnosis of inflammatory bowel disease is critically dependent on the macroscopic pathological features
- please take post-operative specimens and ischaemic bowel resections seriously. They will return to bite you later if poorly done……

# More take home messages

- clean, tidy, standardised assessment
- good macroscopic description showing anatomical and surgical knowledge
- economy of blocks: blocks mean money.....
- accurate measurement in millimetres with no terminal digit preference
- sensible use of gelatin rather than paint
- photography is cheap and easy
- BMS cut-up where appropriate and when appropriately trained
- no amount of sophisticated microscopy can undo a poorly performed  and executed macroscopic assessment, dissection and description
- smile and sing!!

# Further reading

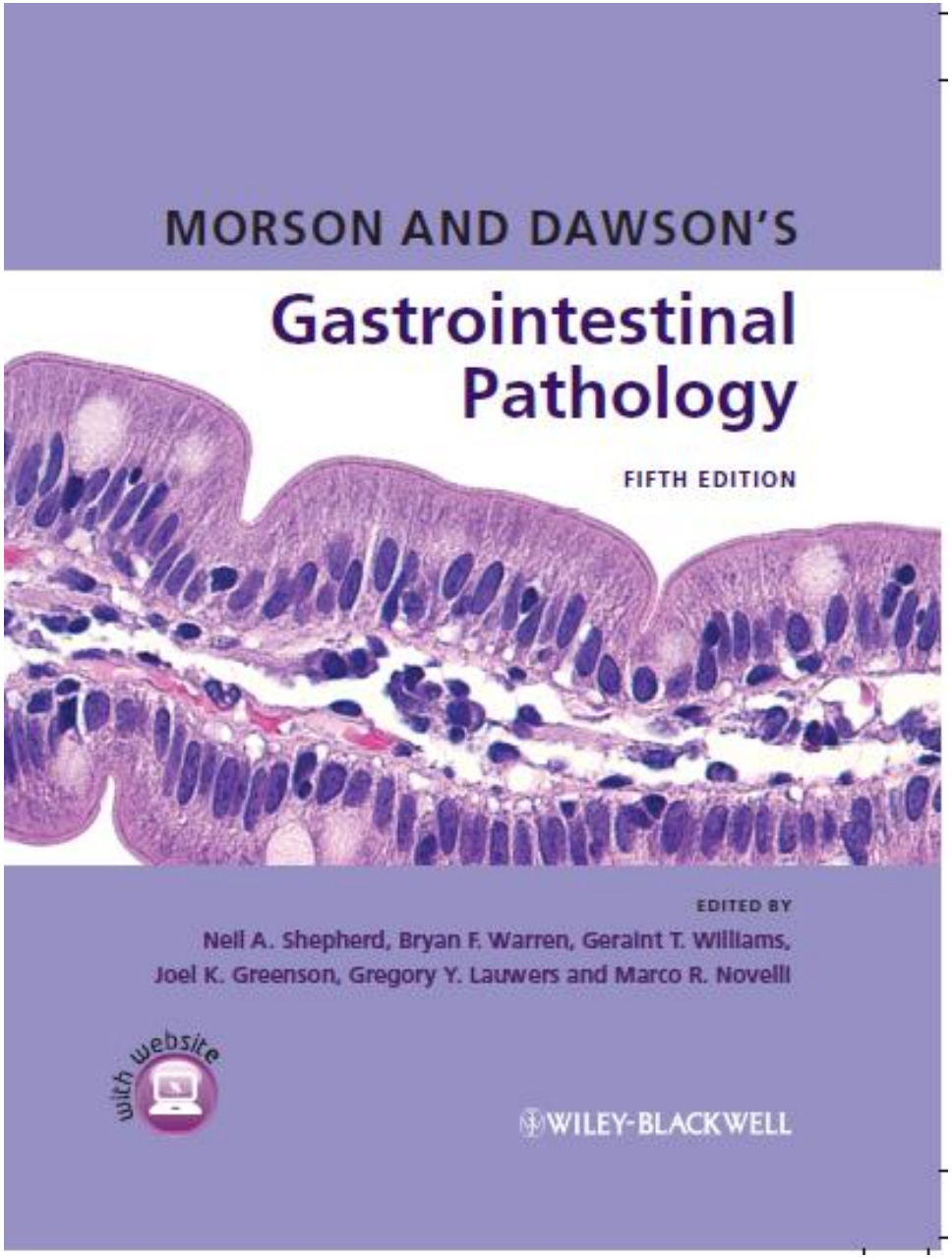


**Datasets and guidelines**

Colorectal cancer, v3

July 2014

at:

www.rcpath.org

# Acknowledgements

Neil Shepherd
Maurice Loughrey
Phil Quirke
Bryan Warren
Geraint Williams

Royal College of Pathologists

MANCHESTER 1824

The University of Manchester

Central Manchester University Hospitals NHS

NHS Foundation Trust

# THANK YOU FOR YOUR ATTENTION
# ANY QUESTIONS?

INTERNATIONAL ACADEMY OF PATHOLOGY

IAMM 1906